Review

Laser-based management of oral leukoplakia: A narrative review by a study group of the World Federation for Laser Dentistry (WFLD)

Kinga Grzech-Leśniak[1,2,A–F*], Paolo Vescovi[3,A–F*], Georgios Romanos[4,5,B–F], Rafał Wiench[6,A–F], Jakub Fiegler-Rudol[7,A–F], Ilaria Giovannacci[3,D–F], Janina Golob Deeb[2,D–F], Zuzanna Grzech-Leśniak[8,9,A–F], Jacek Matys[10,D–F], Aldo Brugnera Junior[11,12,C–F], Mariusz Szuta[13,C–F], Sajee Sattayut[14,C–F], Praveen Arany[15,B–F], Marco Meleti[3,C–F], Maha Taalab[16,B–F], Josep Arnabat-Dominguez[17,D–F], Alessandro Del Vecchio[18,C–F], Jamil Awad Shibli[19,20,A–F], Maciej Misiołek[21,C–F], Octavi Camps-Font[17,D–F], Akira Aoki[22,A–F], Umberto Romeo[18,C–F], Samir Nammour[23,A–F]

[1] Laser Laboratory, Department of Integrated Dentistry, Faculty of Dentistry, Wroclaw Medical University, Poland
[2] Department of Periodontics, School of Dentistry, Virginia Commonwealth University (VCU), Richmond, USA
[3] Oral Medicine and Oral Surgery Laser Unit, Department of Medicine and Surgery, University of Parma, Italy
[4] Department of Periodontics and Endodontics, School of Dental Medicine, Stony Brook University, USA
[5] Department of Oral Surgery, Implant Dentistry and Oral Medicine, Goethe Dental School, Goethe University, Frankfurt am Main, Germany
[6] Department of Periodontal and Oral Mucosa Diseases, Faculty of Medical Sciences in Zabrze, Medical University of Silesia, Katowice, Poland
[7] University Dental Center, Wroclaw Medical University, Poland
[8] Department of Experimental Dentistry, Faculty of Dentistry, Wroclaw Medical University, Poland
[9] Doctoral School, Faculty of Dentistry, Wroclaw Medical University, Poland
[10] Department of Dental Surgery, Faculty of Dentistry, Wroclaw Medical University, Poland
[11] Basic Optics and Applied Life Sciences, National Institutes of Science and Technology (INCT), São Carlos Institute of Physics (IFSC), University of São Paulo (USP), Brazil
[12] Brugnera and Zanin Institute, Biophotonics Laser Center, Instituto Brugnera e Zanin, São Paulo, Brazil
[13] Department of Oral Surgery, Institute of Dentistry, Faculty of Medicine, Jagiellonian University Medical College, Krakow, Poland
[14] Lasers in Dentistry Research Group, Khon Kaen University, Thailand
[15] Department of Oral Biology, School of Dental Medicine, University of Buffalo, USA
[16] Department of Oral Medicine, Periodontology, Oral Diagnosis, and Oral Radiology, Faculty of Dentistry, Alexandria University, Egypt
[17] Dental School, Faculty of Medicine and Health Sciences, University of Barcelona, Institute of Biomedical Research of Bellvitge (IDIBELL), Barcelona, Spain
[18] Department of Oral and Maxillofacial Sciences, Sapienza University of Rome, Italy
[19] Department of Periodontology, Dental Research Division, Universus Veritas Guarulhos University, Brazil
[20] Department of Oral Medicine, Infection and Immunity, Harvard School of Dental Medicine, Boston, USA
[21] Department of Otorhinolaryngology and Oncological Laryngology, Faculty of Medical Sciences in Zabrze, Medical University of Silesia, Katowice, Poland
[22] Department of Periodontology, Graduate School of Medical and Dental Sciences, Institute of Science Tokyo, Japan
[23] Department of Dental Sciences, Faculty of Medicine, University of Liège, Belgium
* These authors contributed equally to this work.

A – research concept and design; B – collection and/or assembly of data; C – data analysis and interpretation;
D – writing the article; E – critical revision of the article; F – final approval of the article

Dental and Medical Problems, ISSN 1644-387X (print), ISSN 2300-9020 (online) *Dent Med Probl*. 2026;63(5):1289–1302

Cite as
Grzech-Leśniak K, Vescovi P, Romanos G, et al. Laser-based management of oral leukoplakia: A narrative review by a study group of the World Federation for Laser Dentistry (WFLD). *Dent Med Probl.* 2026;63(5):1289–1302. doi:10.17219/dmp/226773

DOI
10.17219/dmp/226773

Copyright
Copyright by Author(s)
This is an article distributed under the terms of the Creative Commons Attribution 3.0 Unported (CC BY 3.0) (https://creativecommons.org/licenses/by/3.0/)

Address for correspondence
Kinga Grzech-Leśniak
E-mail: kinga.grzech-lesniak@umw.edu.pl

Funding sources
None declared

Conflict of interest
None declared

Acknowledgements
None declared

Received on April 4, 2026
Reviewed on April 26, 2026
Accepted on August 3, 2026

Published online on October 30, 2026

Abstract

The aim of the review was to systematically synthesize and critically appraise the available evidence from systematic reviews and meta-analyses evaluating the clinical effectiveness, safety and applicability of laser-based therapies in the management of oral leukoplakia (OL), and to develop evidence-based clinical recommendations of the World Federation for Laser Dentistry (WFLD). The search of PubMed/MEDLINE, Embase, Scopus, and the Cochrane Library was conducted to identify systematic reviews and meta-analyses published between 2016 and 2026. Eligible reviews assessed laser-based interventions for OL and reported clinically relevant outcomes. Methodological quality was evaluated using a laser-adapted nine-domain risk-of-bias assessment tool. Ten reviews were included, comprising systematic reviews, meta-analyses and network meta-analyses. Evaluated modalities included CO_2, erbium-doped yttrium aluminium garnet (Er:YAG), erbium, chromium-doped yttrium, scandium, gallium, and garnet (Er,Cr:YSGG), diode, neodymium-doped yttrium aluminium garnet (Nd:YAG), and potassium titanyl phosphate (KTP) lasers, as well as laser-assisted photodynamic therapy (PDT). Overall, laser-based interventions demonstrated recurrence rates comparable to or lower than those associated with conventional surgery, with favorable postoperative outcomes including reduced pain and improved hemostasis. All included reviews were classified as having a low ($n = 6$) or moderate ($n = 4$) risk of bias according to the study-specific assessment framework, although substantial heterogeneity in laser parameters and outcome reporting was observed. Laser-based therapies represent clinically justified options for the management of OL when appropriately selected and integrated with histopathological assessment, adequate margin control, complete lesion removal, and long-term surveillance. However, current evidence does not demonstrate a consistent reduction in the risk of malignant transformation or definitive superiority of any specific laser modality. Heterogeneity in surgical procedures, outcome definitions and study designs underscores the need for standardized reporting and high-quality prospective studies.

Keywords: recurrence, laser therapy, malignant transformation, oral potentially malignant disorders, leukoplakia

Highlights

- Laser-based therapies are effective and safe for the management of oral leukoplakia, with recurrence rates comparable to or lower than those of conventional surgical approaches.
- No surgical intervention, including laser-based techniques, has been shown to reduce the risk of malignant transformation, which is primarily influenced by lesion biology and patient-related factors.
- Adequate surgical margins, appropriate ablation depth and complete lesion removal are key to reducing recurrence in laser-based treatment.
- This narrative review provides a structured framework for the clinical application of lasers in the management of oral leukoplakia.

Introduction

Oral leukoplakia (OL) is one of the most common oral potentially malignant disorders (OPMDs), defined as a white plaque of questionable risk after the exclusion of other known diseases not associated with an increased risk of cancer.[1–3] Its management should be considered within the broader OPMD framework, encompassing oncologic risk reduction, histopathological risk stratification, adequate surgical management, recurrence prevention, and long-term surveillance. With a global prevalence of 0.1–4.5%, OL represents a significant public health concern due to its potential for malignant transformation into oral squamous cell carcinoma.[2–4] Meta-analytic evidence indicates that OL is associated with significantly increased odds of developing oral cancer (summary odds ratio (*SOR*): 3.35; 95% confidence interval (95% *CI*): 3.21–3.50).[5] Malignant transformation rates vary according to clinical characteristics, anatomical site and lesion subtype, with particularly high rates reported for proliferative verrucous leukoplakia (PVL), which may approach 50%.[3,6,7] Although available management strategies include active surveillance, conventional surgical excision, pharmacological interventions, and laser-based therapies,[8,9] no universally accepted, evidence-based management protocol has yet been established.[10,11]

Laser therapy offers potential advantages over conventional surgery, including improved hemostasis, reduced postoperative morbidity, minimal scarring, and the elimination of the need for sutures, which may prevent distortion of the surgical site and enhance surgical precision, particularly for extensive or multifocal lesions.[12,13] Systems in clinical use include CO_2, erbium-doped yttrium aluminium garnet (Er:YAG), erbium, chromium-doped yttrium, scandium, gallium, and garnet (Er,Cr:YSGG), neodymium-doped yttrium aluminium garnet (Nd:YAG), and diode lasers, each with distinct wavelength-specific tissue interaction properties.[12–14] Several clinical and experimental studies have contributed to our understanding of laser–tissue interactions in OPMDs.[15–17] Despite the increasing availability of laser-based treatments, the evidence remains heterogeneous and methodologically limited. Available systematic reviews suggest that laser-based treatment is associated with lower recurrence rates than conventional surgery, but has no consistent effect on malignant transformation.[12] Core clinical determinants, including lesion characteristics, histopathology and the adequacy of surgical margins, are consistent across treatment modalities, supporting a principle-based rather than parameter-driven approach.[13,18] Several clinically relevant questions remain unresolved: whether laser therapy confers advantages beyond

its technical surgical benefits, whether recurrence is driven primarily by treatment modality or lesion biology, and how surgical margins, ablation depth and surgical procedures should be optimized according to histopathological risk.

Objectives

This narrative review, developed by the World Federation for Laser Dentistry (WFLD) study group through literature synthesis and expert consensus, aims to evaluate the clinical effectiveness, safety and applicability of laser-based treatments in the management of OL and to provide evidence-informed clinical recommendations. The specific objectives are to: (1) evaluate the clinical effectiveness of laser treatments, including lesion resolution, recurrence, symptom control, and malignant transformation risk, in comparison with conventional surgical and non-surgical approaches; (2) identify and compare laser modalities and technical procedures; (3) assess safety profiles, postoperative morbidity, and functional and aesthetic outcomes; (4) appraise methodological quality, heterogeneity and knowledge gaps; and (5) establish an initial framework for consensus-based clinical recommendations to guide standardized and safe use of lasers in OL management.

Methodology

This study was designed as a narrative review supported by an analysis of systematic reviews and meta-analyses. Selected methodological principles from the Joanna Briggs Institute (JBI) umbrella review framework were applied to ensure transparency, and reporting followed the PRISMA (Preferred Reporting Items for Systematic reviews and Meta-Analyses) 2020 guidelines.[19–22] The protocol was registered in the PROSPERO (International Prospective Register of Systematic Reviews) database (registration No. CRD420261287719).

PICO question

In patients with oral leukoplakia, does laser-based surgical treatment (excision, ablation or vaporization), compared with conventional surgery, pharmacological treatment or no intervention, improve lesion resolution, recurrence rates, postoperative morbidity, the risk of malignant transformation, and functional or aesthetic outcomes?

Search strategy and study selection

A structured literature search was conducted in PubMed/MEDLINE, Embase, Scopus, and the Cochrane Library using predefined strategies informed by the PICO framework and combining controlled vocabulary, where applicable, with free-text terms related to OL and laser-based interventions. The search covered studies published from January 1, 2016 to January 31, 2026. Broad review filters were applied, where available, in the respective databases. Eligibility was restricted during screening to systematic reviews and meta-analyses reporting extractable data relevant to OL. Records were screened independently by multiple reviewers in 2 stages: first, title and abstract screening, followed by full-text assessment. Disagreements were resolved through consensus. The complete database-specific search strategies and the number of records retrieved are presented in Table 1.

Table 1. Database search strategies, limits and the number of records retrieved

Database	Search syntax	Filters	Records retrieved, *n*
PubMed	("oral potentially malignant disorder*"[tiab] OR "oral potentially malignant lesion*"[tiab] OR "Leukoplakia, Oral"[MeSH] OR leukoplakia[tiab] OR "Lichen Planus, Oral"[MeSH] OR "oral lichen planus"[tiab] OR "Oral Submucous Fibrosis"[MeSH] OR "oral submucous fibrosis"[tiab]) AND ("Laser Therapy"[MeSH] OR "laser surgery"[tiab] OR laser*[tiab] OR "carbon dioxide laser"[tiab] OR "CO_2 laser"[tiab] OR "Er:YAG"[tiab] OR "Er,Cr:YSGG"[tiab] OR "diode laser"[tiab] OR "Nd:YAG"[tiab]) AND (treatment[tiab] OR therapy[tiab] OR excision[tiab] OR ablation[tiab] OR vaporization[tiab])	review; English; January 1, 2016–January 31, 2026	36
Embase	('oral potentially malignant disorder'/exp OR 'oral potentially malignant disorder*':ti,ab OR 'oral potentially malignant lesion*':ti,ab OR 'leukoplakia':ti,ab OR 'oral lichen planus'/exp OR 'oral submucous fibrosis'/exp) AND ('laser therapy'/exp OR 'laser surgery'/exp OR 'laser*':ti,ab OR 'carbon dioxide laser'/exp OR 'CO_2 laser':ti,ab OR 'er:yag laser'/exp OR 'er,cr:ysgg':ti,ab OR 'diode laser'/exp OR 'nd:yag':ti,ab) AND ('treatment':ti,ab OR 'therapy':ti,ab OR 'excision':ti,ab OR 'ablation':ti,ab OR 'vaporization':ti,ab)	review; English; January 1, 2016–January 31, 2026	41
Scopus	TITLE-ABS-KEY("oral potentially malignant disorder*" OR "oral potentially malignant lesion*" OR "leukoplakia" OR "oral lichen planus" OR "oral submucous fibrosis") AND TITLE-ABS-KEY("laser therapy" OR "laser surgery" OR "laser*" OR "CO_2 laser" OR "carbon dioxide laser" OR "Er:YAG" OR "Er,Cr:YSGG" OR "diode laser" OR "Nd:YAG") AND TITLE-ABS-KEY("treatment" OR "therapy" OR "excision" OR "ablation" OR "vaporization")	review; English; January 1, 2016–January 31, 2026	71
Cochrane Library	("oral potentially malignant disorder" OR "oral potentially malignant disorders" OR "oral potentially malignant lesion" OR "oral potentially malignant lesions" OR "OPMD" OR "leukoplakia" OR "oral leukoplakia" OR "oral lichen planus" OR "oral submucous fibrosis") AND ("laser therapy" OR "laser" OR "lasers" OR "laser treatment" OR "high power laser" OR "dental laser" OR "laser surgery" OR "Er:YAG laser" OR "Er,Cr:YSGG laser" OR "Nd:YAG laser" OR "diode laser" OR "CO_2 laser" OR "carbon dioxide laser")	Cochrane reviews; English; January 1, 2016–January 31, 2026	1

Data extraction

Three reviewers extracted data independently using a standardized, pilot-tested form. Extracted review-level information included study characteristics, patient populations, lesion characteristics, as well as anatomical sites, interventions, comparators, and follow-up periods. Laser-related data, where reported, included the laser system (CO_2, Er:YAG, Er,Cr:YSGG, diode, Nd:YAG, or potassium titanyl phosphate (KTP)), wavelength, power output, energy or radiant exposure, application mode, treatment duration, number of sessions, surgical margins, and ablation or excision depth. For laser-assisted photodynamic therapy (PDT), information on the photosensitizer, light source, wavelength, irradiation parameters, and the number of treatment sessions was also extracted, where available. Outcomes included lesion response or resolution, recurrence, malignant transformation, postoperative pain and complications, bleeding and hemostasis, functional and aesthetic outcomes, patient-reported symptoms, and adverse events. Discrepancies were resolved through consensus, with arbitration by an additional senior reviewer when necessary. Missing information was sought in supplementary materials or by contacting the corresponding authors and was recorded as "not reported" when it could not be retrieved. The extracted data was collated to assess the consistency and clinical applicability of the available evidence and to inform the development of the WFLD clinical recommendations.

Risk of bias and quality assessment

The methodological quality of each included review was assessed independently by 3 reviewers using a structured framework developed for this study, informed by AMSTAR-2 (A MeaSurement Tool to Assess systematic Reviews, version 2) and adapted to incorporate laser-specific domains relevant to reproducibility, technical transparency and clinical interpretation.

The assessment criteria included: (1) description of the laser system and its parameters (wavelength, power, fluence, and application mode); (2) definition of treatment protocols, the number of sessions, and a priori case selection criteria, including lesion subtype, clinical and histopathological features, and patient-related factors; (3) specification of outcomes, including lesion resolution, recurrence, postoperative morbidity, and malignant transformation; (4) inclusion of appropriate comparator groups; (5) transparent inclusion criteria and characterization of the patient population; (6) measures to control bias, including randomization, allocation concealment and blinding; (7) appropriateness and reproducibility of statistical analyses; (8) completeness of outcome and safety reporting, including follow-up duration; and (9) disclosure of funding and conflicts of interest.

Each domain was scored dichotomously (1 = fulfilled, 0 = not fulfilled), yielding a total score of 0–9. Reviews were categorized as having a low (7–9), moderate (4–6) or high (0–3) risk of bias. Disagreements were resolved through discussion or arbitration by a fourth reviewer. The framework was informed by the *Cochrane Handbook for Systematic Reviews of Interventions* and adapted to address heterogeneity in laser-specific reporting.[21]

Consensus development process

The evidence synthesis and consensus process was conducted by the WFLD study group, comprising clinicians and researchers with expertise in oral surgery, oral medicine, oral pathology, laser dentistry, and OPMDs. A structured review of the available evidence was combined with iterative expert discussions focused on clinically relevant principles and their practical implementation. Disagreements were resolved through further discussion until consensus was reached among the contributing experts. When evidence was limited or heterogeneous, clinical statements were intentionally formulated as conditional, principle-based recommendations rather than prescriptive treatment protocols. This evidence-informed and consensus-based approach was consistent with the methodology previously applied in the development of the official WFLD clinical recommendations for the laser-assisted management of other complex oral conditions. The objective was to provide a clinically oriented framework for the safe and appropriate use of lasers in the management of OL.

Results

Study selection

The database search identified 149 records (PubMed, n = 36; Embase, n = 41; Scopus, n = 71; and the Cochrane Library, n = 1). After the removal of 81 duplicates, 68 records underwent title and abstract screening, of which 55 were excluded. The remaining 13 reports were retrieved and assessed for eligibility. Two additional reports were identified through citation searching and assessed for eligibility. Of the 15 full-text reports assessed, 5 were excluded: 2 because they were not systematic reviews or meta-analyses; and 3 because they addressed laryngeal or vocal fold leukoplakia rather than OL. Ultimately, 10 systematic reviews and meta-analyses met the eligibility criteria and were included in the review (Fig. 1).

Risk of bias and quality assessment

Six reviews were classified as having a low risk of bias and 4 as having a moderate risk of bias; none was classified as having a high risk of bias. Reviews categorized as having a low risk of bias generally demonstrated transparent

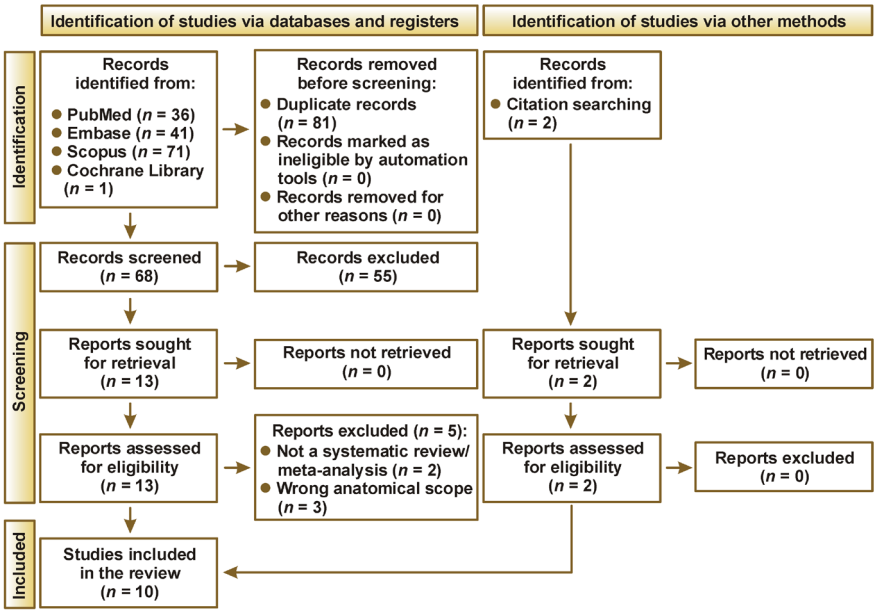

Fig. 1. PRISMA (Preferred Reporting Items for Systematic reviews and Meta-Analyses) 2020 flow diagram illustrating the study selection process

methodology, adequate reporting of intervention parameters, and appropriate statistical analyses.[12,13,23–26] Studies categorized as having a moderate risk of bias showed incomplete reporting of irradiation parameters, insufficient lesion characterization, absent or inadequately defined comparator groups, and limited assessment of potential confounding factors.[27–31] Common limitations across the included reviews encompassed substantial heterogeneity in treatment protocols, inconsistent outcome definitions, limited availability of randomized controlled trials (RCTs), and a potential overlap among primary studies. The extent of overlap among primary studies was not formally quantified. Detailed results are presented in Table 2.

Characteristics of the included reviews

The 10 included reviews evaluated CO_2, Er:YAG, Er,Cr:YSGG, Nd:YAG, diode, and KTP lasers, as well as laser-assisted PDT. Individual reviews included between 11 and 80 primary studies, although not all primary studies specifically addressed OL in reviews with broader eligibility

Table 2. Results of the risk-of-bias assessment

Study	Domain									Total score (0–9)	Risk of bias
	1	2	3	4	5	6	7	8	9		
Abdul 2025[27]	1	1	1	0	1	0	0	1	0	5	moderate
Bhattarai et al. 2024[23]	1	1	1	1	1	1	1	1	1	9	low
Datarkar et al. 2025[13]	1	1	1	1	1	1	1	1	1	9	low
Dong et al. 2019[28]	1	1	1	0	1	0	1	1	0	6	moderate
Gondivkar et al. 2018[24]	1	1	1	1	1	1	1	1	1	9	low
Li et al. 2019[29]	1	1	1	0	1	0	0	1	0	5	moderate
Luo et al. 2024[25]	1	1	1	1	1	1	1	1	1	9	low
Mogedas-Vegara et al. 2016[31]	1	1	1	0	1	0	0	1	0	5	moderate
de Pauli Paglioni et al. 2020[12]	1	1	1	1	1	1	1	1	1	9	low
Proaño-Haro et al. 2021[26]	1	1	1	0	1	1	1	1	1	8	low

Each domain was scored dichotomously (1 = fulfilled, 0 = not fulfilled). Reviews were categorized as having a low (7–9), moderate (4–6) or high (0–3) risk of bias.

criteria.[12,13,23–29,31] The CO_2 laser was the most extensively investigated modality and was evaluated in systematic reviews addressing recurrence, malignant transformation, postoperative outcomes, and comparisons with conventional surgery or other treatment modalities.[12,13,23,28,31] Although some analyses suggested favorable recurrence outcomes following CO_2 laser treatment, the findings were heterogeneous, and no consistent reduction in the risk of malignant transformation compared with conventional treatment was demonstrated.[12,28] Combined laser excision and vaporization were associated with particularly favorable recurrence outcomes in 1 large systematic review and meta-analysis.[23]

Evidence concerning Er:YAG and Er,Cr:YSGG lasers was derived primarily from a network meta-analysis and a limited number of comparative primary studies. These modalities achieved favorable rankings for selected outcomes, including recurrence, intraoperative bleeding and postoperative pain; however, the certainty and generalizability of these findings remained limited.[25] Evidence for diode, Nd:YAG and KTP lasers was comparatively sparse and was generally derived from small subsets of primary studies included in broader reviews.[12,23,25,31]

Three reviews evaluated PDT using photosensitizers such as 5-aminolevulinic acid (ALA), methylene blue (MB), Photofrin, Photosan, temoporfin (mTHPC; Foscan), hematoporphyrin derivatives, and chlorin e6.[24,27,29] Reported response rates varied substantially based on lesion type, photosensitizer, irradiation protocol, and outcome definition, limiting direct comparisons and the extrapolation of findings specifically to OL. The review addressing PVL reported a high pooled recurrence rate and found insufficient evidence that any available treatment reliably prevents recurrence in this particularly aggressive subtype.[26] Overall, substantial heterogeneity in lesion classification, intervention protocols, comparators, follow-up periods, and outcome definitions limited comparability across the included reviews. The characteristics of the included reviews are presented in Table 3.

Discussion

Clinical effectiveness of laser therapies

This narrative review contextualizes laser-assisted interventions within the broader principles governing OPMD management rather than serving as a purely technical review. Across the available evidence, recurrence control, adequate surgical margins, histopathological risk stratification, and long-term surveillance represent more clinically relevant determinants of outcome than the specific laser modality.

Laser-based therapies were most consistently associated with effective intraoperative hemostasis, reduced postoperative morbidity, and recurrence rates comparable to or lower than those observed following conventional surgery.[8,32–34] Potential advantages for the management of extensive or multifocal lesions have been suggested, although these observations are derived predominantly from heterogeneous observational data and therefore remain speculative. Lesion characteristics, dysplasia grade, multifocality, anatomical location, and margin adequacy were identified across multiple reviews as important determinants of recurrence and oncologic outcomes, irrespective of the laser modality used.[12,23,26,31]

Mechanisms of action and tissue interaction

CO_2 lasers (10,600 nm) exhibit high absorption in tissue water, enabling precise superficial ablation with limited peripheral thermal spread, and remain the most extensively studied modality for OL.[13,31,32] Er:YAG (2,940 nm) and Er,Cr:YSGG (2,780 nm) lasers exhibit even greater absorption in water, resulting in narrower thermal damage zones than those associated with CO_2 lasers (median (*Me*): 30.9 μm vs. 72.6 μm), with potential advantages for tissue preservation and healing. However, clinical evidence remains limited.[35–37] Diode (808–980 nm) and Nd:YAG (1,064 nm) lasers exhibit lower absorption in water and deeper tissue penetration, promoting hemostasis while potentially increasing the risk of collateral thermal damage if treatment parameters are not carefully controlled.[38] In anatomically sensitive areas, such as the gingiva and palate, a tangential rather than perpendicular approach may help minimize thermal injury to the periosteum, bone or dental structures.[14,39]

Recurrence rates

A 2024 systematic review and meta-analysis of 80 studies involving 7,614 samples reported a pooled recurrence proportion of approx. 22% for laser-based approaches, with a network meta-analysis indicating that combined protocols (excision followed by vaporization) ranked among the most favorable strategies for reducing recurrence.[23] A 2025 meta-analysis on CO_2 laser treatment reported a trend toward lower recurrence rates compared with other modalities (odds ratio (*OR*): 0.36, 95% *CI*: 0.12–1.04), although this difference did not reach statistical significance ($p = 0.06$).[13] Overall, the available data suggests a possible benefit of laser-assisted treatment in reducing recurrence rates, but the findings remain heterogeneous and inconclusive.

Postoperative outcomes

Laser-based therapies are generally associated with lower pain, improved hemostasis and reduced intraoperative bleeding compared with conventional surgery. An RCT reported significantly greater pain and swelling following cold blade surgery during the first 3 postoperative days

Table 3. Characteristics and key findings of the included systematic reviews and meta-analyses

Study	Study type	Primary studies included, *n*	Interventions	Databases searched	Publication years of included studies	Study designs	Results
Abdul 2025[27]	SR	11	PDT (ALA, MB)	PubMed, Embase, Cochrane Library, Scopus, Web of Science, CINAHL, PsycInfo	2005–2022	clinical studies	• ALA–PDT is an effective and well-tolerated treatment for oral potentially malignant disorders; however, treatment outcomes vary substantially depending on lesion type and biological behavior. • Treatment outcomes are strongly influenced by lesion-specific characteristics, including clinical subtype (e.g., leukoplakia vs. verrucous hyperplasia or erythroleukoplakia), as well as PDT parameters and treatment protocols. • The heterogeneity of the included lesion types limits direct extrapolation of the findings to OL alone, underscoring the need for disease-specific interpretation and individualized treatment strategies. • Standardized protocols and further well-designed studies, with stratification according to lesion type, are required to optimize clinical outcomes.
Bhattarai et al. 2024[23]	SR, MA	80	laser surgery, scalpel surgery, cryosurgery, PDT	Embase, PubMed, Scopus, Web of Science	1968–2024	RCTs, observational studies	• Laser-based surgery was associated with lower recurrence rates of OL than other surgical modalities. • Combined laser excision and vaporization was associated with the most favorable recurrence outcomes. • Higher recurrence rates were correlated with retromolar or multifocal OL, non-homogeneous lesions, older age, female sex, inadequate margins, retrospective study design, and betel quid chewing.
Datarkar et al. 2025[13]	SR, MA	16	CO_2 laser vs. scalpel, cryosurgery, diode laser	PubMed, Scopus, Embase, Web of Science, CENTRAL, PROSPERO, and others	2000–2023	RCTs, non-RCTs	• CO_2 laser demonstrated a statistically non-significant trend toward lower recurrence rates (*OR*: 0.36; $p = 0.06$). • No significant difference in postoperative pain was observed between treatments.
Dong et al. 2019[28]	SR, MA	24	CO_2 laser	Cochrane Library, Embase, PubMed, Web of Science, Scopus	NR (up to 2018)	RCTs, retrospective cohort studies, case–control studies, prospective studies	• A statistically non-significant trend toward a higher risk of malignant transformation was observed in males with homogeneous OL who did not use tobacco or alcohol. • Laser surgery has a limited influence on the risk of malignant transformation. • The available evidence is insufficient to identify risk factors for malignant transformation after CO_2 laser treatment.
Gondivkar et al. 2018[24]	SR	26	PDT (ALA, Photofrin, Photosan, mTHPC, hematoporphyrin derivatives, chlorin e6)	PubMed/MEDLINE, Google Scholar, Embase, ISI Web of Knowledge	1985–2015	RCTs, retrospective cohort studies, case–control studies, prospective studies	• PDT achieved a complete response in 22.58–100% of cases, a partial response in 4–66%, and no response in 0–38.70% of cases involving potentially malignant disorders. • In HNSCC, complete response rates ranged from 16% to 100%. • PDT appears to be effective in the management of oral potentially malignant disorders and HNSCC.
Li et al. 2019[29]	SR	16	PDT (ALA, Photofrin, MB, chlorin e6)	PubMed/MEDLINE, Embase, ISI Web of Knowledge, Ovid, CNKI, Wanfang Data	NR (up to 2018)	clinical studies	• PDT is a useful non-surgical treatment for OL. • The evidence remains insufficient due to the limited number of randomized trials, short follow-up periods and heterogeneous PDT protocols. • Well-designed RCTs with long-term follow-up and standardized parameters are required.
Luo et al. 2024[25]	SR, MA	11	Er:YAG laser, Er,Cr:YSGG laser, CO_2 laser + PDT, surgery	PubMed, Embase, Web of Science, Cochrane Library	1946–2023	RCTs	• Er,Cr:YSGG laser treatment was associated with the lowest estimated recurrence rate among the treatments compared. • Er,Cr:YSGG laser treatment ranked most favorably for recurrence reduction and pain reduction, whereas Er:YAG laser treatment was associated with reduced intraoperative bleeding. • No severe adverse events were reported. • For non-homogeneous OL, Er:YAG, Er,Cr:YSGG, and CO_2 + PDT may represent promising alternatives to surgery. • Further high-quality randomized trials are needed.
Mogedas-Vegara et al. 2016[31]	SR	33	CO_2 laser (including comparisons with cold knife surgery, Nd:YAG laser, KTP laser)	PubMed/MEDLINE	1981–2015	retrospective and prospective clinical studies, comparative studies	• CO_2 laser is the standard treatment approach for OL due to its high efficacy and low morbidity. • Randomized comparative trials evaluating other laser modalities are lacking. • Risk factors for recurrence and malignant transformation remain undefined.
de Pauli Paglioni et al. 2020[12]	SR, MA	36	CO_2 laser, Nd:YAG laser, Er:YAG laser, KTP laser, diode lasers vs. conventional surgery or no control	PubMed/MEDLINE, Scopus, Embase	NR (up to 2019)	RCTs, retrospective cohort studies, case–control studies, prospective studies	• Laser excision of OL may be associated with lower recurrence rates compared with conventional treatment. • No reduction in the risk of malignant transformation has been demonstrated.
Proaño-Haro et al. 2021[26]	SR, MA	12	CO_2 laser	PubMed/MEDLINE, Embase, Web of Science	1985–2020	clinical trials, retrospective and longitudinal observational studies, case series (≥10 patients)	• A global effect MA of pooled proportions demonstrated a recurrence rate of 67.2% (95% *CI*: 48.3–81.8). • The available evidence is insufficient to conclude that any available treatment strategy effectively reduces recurrence in proliferative verrucous leukoplakia.

SR – systematic review; MA – meta-analysis; NR – no restriction; 95% *CI* – 95% confidence interval; PDT – photodynamic therapy; ALA – 5-aminolevulinic acid; MB – methylene blue; mTHPC – meta-tetra(hydroxyphenyl) chlorin; Er:YAG – erbium-doped yttrium aluminium garnet; Er,Cr:YSGG – erbium, chromium-doped yttrium, scandium, gallium, and garnet; Nd:YAG – neodymium-doped yttrium aluminium garnet; KTP – potassium titanyl phosphate; CINAHL – Cumulative Index to Nursing and Allied Health Literature; CENTRAL – Cochrane Central Register of Controlled Trials; PROSPERO – International Prospective Register of Systematic Reviews; CNKI – China National Knowledge Infrastructure; OL – oral leukoplakia; *OR* – odds ratio; HNSCC – head and neck squamous cell carcinoma; RCTs – randomized controlled trials.

($p < 0.05$),[40] while another RCT comparing CO_2 laser, Er:YAG and conventional scalpel surgery demonstrated significantly shorter operative times with laser-based approaches ($p < 0.001$) and less intraoperative bleeding with the CO_2 laser ($p < 0.001$).[37] However, a 2025 meta-analysis found no significant differences in postoperative pain between CO_2 laser treatment and other modalities (standardized mean difference (*SMD*): –0.16, 95% *CI*: –1.37–1.05),[13] reflecting substantial variability among the studies. These findings should be interpreted with caution given the heterogeneity in study designs and the limited availability of high-quality randomized evidence.[14,37,39–42]

Lesion resolution

Complete response rates following laser therapy vary considerably, ranging from approx. 50% to over 90%, depending on lesion characteristics, the degree of dysplasia, multifocality, and treatment modality. A prospective study using a high-power diode laser (808 nm) reported a complete response in 93.5% of cases, with a low recurrence rate during follow-up,[14] while Er:YAG laser treatment demonstrated complete and partial responses in a substantial proportion of lesions, although recurrence remained a concern.[14,35] A retrospective study using a CO_2 laser noted a permanent treatment success rate of 97.8% at 6-year follow-up after complete excision to a depth of ≥1 mm with a 3-mm margin of healthy-appearing tissue. However, the cohort comprised predominantly homogeneous leukoplakias without dysplasia, suggesting that the favorable outcomes may reflect lesion characteristics rather than the technical superiority of the laser modality.[15]

Photodynamic therapy as an adjunctive approach

Photodynamic therapy combines a photosensitizing agent, commonly ALA or MB, a light source operating in the red spectrum (approx. 630–660 nm), and molecular oxygen to generate reactive oxygen species (ROS) that exert cytotoxic effects on dysplastic cells. Systematic reviews have reported substantial heterogeneity in photosensitizers, irradiation parameters, treatment schedules, lesion characteristics, and outcome definitions.[24,27,29] A systematic review addressing OL reported pooled complete and partial response rates of 32.9% and 43.2%, respectively, corresponding to an overall response rate of 76.1%.[29] Ablative fractional laser-assisted PDT achieved an overall positive response rate of 87.5%, including a complete response rate of 62.5%, in a retrospective study with a 3-year follow-up period.[43] Photodynamic therapy with ALA has also demonstrated promising clinical outcomes, suggesting that laser pre-treatment may improve photosensitizer penetration in selected lesions.[34] Nevertheless, the available evidence remains heterogeneous, and these findings do not establish the superiority of any specific photosensitizer, light source or laser-assisted PDT protocol.[24,25,27,29]

Malignant transformation

The available evidence has not demonstrated a consistent or statistically significant difference in malignant transformation rates following laser therapy compared with conventional treatment approaches. Reported rates range from approx. 1% to 15%, with longer follow-up generally associated with higher cumulative rates.[12,32,44–48] Recurrent leukoplakia is associated with an approx. 7-fold higher risk of malignant transformation compared with non-recurrent lesions,[23] highlighting the clinical importance of long-term disease monitoring. Established risk factors include dysplasia severity, lesion heterogeneity, anatomical location, and recurrence status.[28,49,50] The risk of malignant transformation appears to be influenced primarily by lesion biology and patient-related factors rather than the surgical modality employed.

Comparative effectiveness of laser devices

The CO_2 laser has the largest evidence base among the laser modalities used for OL, with studies reporting favorable recurrence control, effective hemostasis and acceptable postoperative outcomes. Nevertheless, the available evidence remains heterogeneous, and neither consistent superiority over other surgical approaches nor a reduction in the risk of malignant transformation has been demonstrated.[12,13,23,28,31]

The Er:YAG laser produces a narrower zone of thermal damage than the CO_2 laser, which may be advantageous for tissue preservation and histopathological assessment.[37] In a retrospective comparative study, Er:YAG treatment was associated with a significantly better clinical outcome than conventional scalpel surgery ($p = 0.015$). However, no significant overall differences were observed among the 5 treatment modalities evaluated.[45] The consistent superiority of Er:YAG laser treatment over CO_2 laser treatment or conventional surgery has not been established in systematic reviews.[12,25,31]

Diode lasers provide effective hemostasis and may facilitate outpatient excision or ablation of OL. However, the available evidence is derived predominantly from small observational or non-comparative studies, and robust conclusions regarding recurrence control and oncologic outcomes cannot be drawn.[14,38,51–53]

Evidence concerning the KTP laser remains limited. A retrospective comparative study reported a lower recurrence rate following KTP laser treatment than after CO_2 laser treatment.[52] However, the available systematic reviews and limited comparative evidence are insufficient to establish the superiority of the KTP laser over the CO_2 laser or other laser modalities.[12,31,52] The selection of a laser modality should therefore be guided by lesion characteristics, anatomical location, the intended surgical procedure, histopathological requirements, and operator experience.

Table 4. Results of studies reporting surgical margin widths and excision depths in relation to the reduction of recurrence of oral leukoplakia (OL)

Study	Lesions evaluated	Peripheral surgical margin width	Depth
Nammour et al. 2017[15]	homogeneous OL	3 mm	minimum 1 mm
Romeo et al. 2020[61]	non-dysplastic OL	≥3 mm	~1 mm
Shivhare et al. 2022[55]	mixed homogeneous and non-homogeneous OL	3–4 mm	ablation: 1 mm excision: 3–5 mm
Vilar-Villanueva et al. 2023[56]	OL	≥3 mm	not specified
Dutra et al. 2026[57]	OL (91 studies included in a scoping review)	≥5 mm recommended	not specified

Technical considerations and optimal parameters

Adequate surgical margin width is a critical determinant of recurrence rates in homogeneous OL, with favorable and sustained outcomes reported even during long-term follow-up.[15] Surgical margins of ≤3 mm have been associated with higher recurrence rates, whereas margins of 3–5 mm may reduce the risk of recurrence.[54–56] However, this relationship varies considerably according to lesion subtype. Proliferative verrucous leukoplakia exhibits high recurrence rates even with surgical margins that exceed 3 mm. In general, a margin extension of 5 mm is considered optimal.[57] For vaporization, a safety margin of approx. 3 mm beyond the clinically visible lesion boundary has been associated with lower recurrence rates ($p < 0.05$) (Table 4).[15,58–61]

Collectively, these findings support lesion-specific surgical planning rather than uniform excision protocols.

Diagnostic utility

Incisional biopsy with histopathological evaluation remains mandatory before any treatment of OL, regardless of the surgical modality used. Laser-induced thermal effects may alter tissue architecture, potentially affecting histopathological interpretation and the assessment of surgical margins. The intraoperative and postoperative clinical advantages of laser surgery, including improved hemostasis and reduced morbidity, are well documented. However, current evidence does not support the diagnostic superiority of lasers over conventional biopsy techniques. These considerations highlight the importance of appropriate surgical technique and wavelength selection when laser-assisted biopsy is performed.[61–65]

Safety and complications

The findings of this review indicate that laser-based therapies for OL are generally well tolerated and associated with low complication rates. Serious adverse events were infrequently reported, with most studies noting minimal postoperative morbidity.[25,32,34] Common transient side effects include mild to moderate pain, swelling and temporary limitation of mouth opening, typically peaking within the first few days after treatment.[48] Wound healing is generally satisfactory, with minimal scarring, although variability in healing time has been reported, with some cases requiring several weeks for complete re-epithelialization.[60] Rare complications, including pyogenic granuloma formation, fibrosis and persistent discomfort have been described.[39,45,60] The reporting of adverse events remains inconsistent across studies, which may limit the accuracy of safety assessments.[12,32,33,46] As expected, no association between surgical modality (laser-based or conventional) and the risk of malignant transformation has been demonstrated. The risk of malignant transformation appears to be influenced by the biological and histological characteristics of the lesions and a history of head and neck cancer.[66] Nevertheless, these findings must be interpreted with caution due to the limited availability of long-term oncologic data (Table 5).[12,32,33,45,67]

Limitations of the evidence

This narrative review confirms that the overall quality of the available evidence remains limited. Substantial clinical and methodological heterogeneity in laser devices, treatment parameters and protocols precludes reliable quantitative synthesis. Outcome definitions, including those for recurrence rates, lesion resolution and malignant transformation, varied considerably, and long-term follow-up was frequently insufficient. The majority of the studies were small, non-randomized and inadequately controlled. These limitations underscore the need for well-designed RCTs with standardized protocols, uniform outcome evaluation and long-term follow-up.

Limitations of the review process

The search was restricted to English-language publications, and gray literature was excluded, introducing a potential risk of language and publication bias. Relevant clinical data was frequently unavailable, preventing subgroup analyses according to dysplasia grade, lesion site or history of exposure to relevant risk factors. Future studies

Table 5. Summary of laser modalities, treatment parameters, clinical effects, and levels of evidence

Laser modality	Wavelength [nm]	Application mode	Commonly reported treatment parameters	Key clinical effects	Level of evidence	Key references
CO_2 laser	10,600	excision, ablation, vaporization	power output: 4–6 W; focused or defocused mode; safety margin: ≥3 mm	most extensively studied laser modality; effective hemostasis and generally favorable postoperative outcomes; varying recurrence outcomes across studies	high	12,13,15,28,31,32,44,47,52
Er:YAG laser	2,940	excision, ablation	pulse energy: ~50 mJ; frequency ~50 Hz; shallow penetration	narrower zone of thermal damage (~30.9 µm); favorable healing; reduced scarring; variable recurrence rates	moderate	12,25,35–37,45
Er,Cr:YSGG laser	2,780	excision, ablation	treatment parameters were variably reported and often grouped with those of Er:YAG lasers	reduced thermal injury; limited recurrence and oncologic outcomes	low to moderate	25,34
Diode laser	808–980	excision, ablation	continuous-wave mode; power output: 1.5–2.0 W	high complete response rates of up to 93.5%; excellent hemostasis; minimal postoperative pain; feasibility of outpatient treatment	moderate	14,38,53,55,60
Nd:YAG laser	1,064	ablation, coagulation	parameters inconsistently reported	deep tissue penetration; effective coagulation; increased risk of collateral thermal damage	low	12,31,33,36,59,62
KTP laser	532	excision, ablation	parameters inconsistently reported	lower recurrence than CO_2 laser treatment in a comparative study; effective vascular control	low	12,31,52
Laser-assisted PDT (ALA–PDT, MB–PDT)	light source-dependent	ablation + PDT	ALA, MB, Photofrin, Photosan, Foscan, hematoporphyrin derivatives, or chlorin e6; irradiation parameters and the number of sessions varied considerably	overall response of approx. 76.1% in a systematic review; a response of 87.5% for ablative fractional laser-assisted PDT; promising outcomes with Waterlase-assisted ALA–PDT, but protocols remained heterogeneous	moderate	24,25,27,29,34,43

The parameters shown are examples reported in individual studies and should not be interpreted as standardized or universally recommended settings. Selection must take into account the device, delivery system, tissue characteristics, and treatment objective.

may benefit from integrating an expert consensus with structured evidence synthesis to minimize subjective interpretation and facilitate the development of clear recommendations based strictly on clinical and histopathological considerations.

Implications for practice, policy and future research

Laser-based therapies are a valid treatment option for selected patients with OL, particularly when lesion extent, multifocality or anatomical constraints limit conventional surgery. Laser excision enables precise lesion removal with effective hemostasis, whereas laser ablation may be considered for superficial or anatomically challenging lesions. The use of lasers does not eliminate the need for histopathological assessment, risk-stratified patient selection or long-term surveillance, all of which remain essential components of OL management. Consensus-based frameworks addressing indications for excision versus vaporization, safety margins, the documentation of laser parameters, and follow-up standards are urgently needed, alongside structured training and credentialing. Future RCTs should compare laser modalities with conventional surgery, incorporate extended follow-up periods, and stratify patients according to dysplasia grade and lesion subtype, with endpoints including recurrence-free survival, malignant transformation and quality of life.

Conclusions

Laser-based management of OL offers surgical precision, tissue preservation and reduced postoperative morbidity, with recurrence rates comparable to or lower than those associated with conventional surgery when adequate surgical margins and complete removal of the lesion to an adequate depth are achieved.

Current evidence does not demonstrate a consistent effect of laser treatment on the risk of malignant transformation in OL, which appears to be influenced by lesion biology and patient-related factors. Clinical management should integrate histopathological findings, lesion characteristics and the patient's individual risk profile, with an emphasis on surgical margin control, case selection and long-term follow-up. Within the limitations of the available evidence, laser-based therapies constitute a clinically justified component of contemporary OL management when applied within a structured framework, encompassing diagnosis, adequate procedures and surveillance.

Table 6. General therapeutic principles for laser-based management of oral leukoplakia (OL)

Principle	Clinical recommendation
Histopathological assessment is mandatory	Histopathological assessment is mandatory before laser treatment. Representative tissue samples should be obtained and evaluated prior to laser excision, ablation or vaporization.
Laser therapy is a technical modality, not a biological modifier	Laser treatment provides surgical advantages (improved hemostasis, precision and reduced morbidity) but does not eliminate field cancerization or the lesion's intrinsic malignant potential.
Patient selection and risk stratification are essential	Treatment planning should consider lesion subtype (homogeneous vs. non-homogeneous), size, anatomical location, severity of dysplasia, multifocality, history of recurrence, history of squamous cell carcinoma of the upper aerodigestive tract, and patient-related risk factors (tobacco use, alcohol consumption, age, and comorbidities).
Recurrence prevention is a primary clinical objective	Complete lesion removal with adequate surgical margins should be prioritized over superficial ablation. Surgical margin width should be determined according to histopathological findings.
Recommended surgical margins (guidance framework)	≥3 mm for lesions without dysplasia; ≥5 mm for lesions with mild to moderate dysplasia; ≥10 mm for lesions with severe dysplasia or carcinoma in situ
Management of suspected or microinvasive carcinoma	Preoperative imaging (e.g., MRI) is recommended. Surgical excision should include margins of ≥1 cm in all directions; lesions involving the gingiva or hard palate may require resection of the underlying bone (osteotomy).
Laser parameters and treatment intent must be documented	Detailed and transparent reporting of the laser wavelength, power output, energy settings, and treatment protocol is essential for reproducibility and clinical interpretation, even when strict standardization is not feasible.

MRI – magnetic resonance imaging.

General principles for the clinical management of oral leukoplakia according to the WFLD study group

Laser-based interventions in OL may serve as: (A) adjuncts to clinical examination; (B) diagnostic support through laser-assisted biopsy; and (C) surgical management with adequate margin control and complete lesion depth ablation control. The consensus-informed clinical principles developed by the WFLD study group are summarized in Table 6.

General therapeutic principles

1. Histopathological assessment is mandatory before laser management. Following histopathological assessment, laser ablation may be considered for appropriately selected lesions.
2. Laser treatment represents a surgical modality rather than a biological modifier. It does not eliminate field cancerization or the intrinsic malignant potential of the lesion.
3. Risk stratification is essential, incorporating lesion subtype, size, location, dysplasia grade, multifocality, history of recurrence, prior squamous cell carcinoma of the upper aerodigestive tract, and patient-related risk factors, including tobacco use, alcohol consumption and relevant comorbidities.
4. Recurrence prevention requires complete lesion removal, with adequate surgical margins tailored to the histopathological risk:
   - ≥3 mm of clinically healthy-appearing marginal mucosa, with complete lesion ablation to an appropriate depth, for lesions without dysplasia;
   - ≥5 mm for lesions with mild to moderate dysplasia;
   - ≥10 mm for lesions with severe dysplasia or carcinoma in situ. When microinvasive carcinoma is suspected, preoperative magnetic resonance imaging (MRI) is recommended. Surgical margins of ≥1 cm are required, and osteotomy should be considered for gingival or palatal localizations.

Safety and operator requirements

Procedures should be performed by clinicians with appropriate training in laser dentistry and OPMD management, in accordance with established laser safety standards. Patients must be informed that laser therapy does not eliminate the need for long-term surveillance.

Trial registration

The study was registered prospectively in the PROSPERO database (registration No. CRD420261287719).

Ethics approval and consent to participate

Not applicable.

Data availability

The datasets generated and/or analyzed during the current study are available from the corresponding author on reasonable request.

Consent for publication

Not applicable.

Use of AI and AI-assisted technologies

AI-assisted tool (Grammarly AI; Superhuman Platform Inc., San Francisco, USA) was used exclusively for language editing and improvement of readability. No AI tools were used for data analysis, interpretation or generation of scientific conclusions. All content was reviewed and approved by the authors.

ORCID iDs

Kinga Grzech-Leśniak https://orcid.org/0000-0002-5700-4577
Paolo Vescovi https://orcid.org/0000-0002-2223-3716
Georgios Romanos https://orcid.org/0000-0002-7745-5957
Rafał Wiench https://orcid.org/0000-0001-5673-7413
Jakub Fiegler-Rudol https://orcid.org/0009-0009-3173-9389
Ilaria Giovannacci https://orcid.org/0000-0001-8157-4046
Janina Golob Deeb https://orcid.org/0000-0002-3189-0136
Zuzanna Grzech-Leśniak https://orcid.org/0000-0001-6109-6809
Jacek Matys https://orcid.org/0000-0002-3801-0218
Aldo Brugnera Junior https://orcid.org/0000-0002-8634-743X
Mariusz Szuta https://orcid.org/0000-0002-7182-4811
Sajee Sattayut https://orcid.org/0000-0001-7111-9381
Praveen Arany https://orcid.org/0000-0002-6116-2340
Marco Meleti https://orcid.org/0000-0002-9111-3224
Maha Taalab https://orcid.org/0000-0003-3586-6747
Josep Arnabat-Dominguez https://orcid.org/0000-0003-1653-8043
Alessandro Del Vecchio https://orcid.org/0009-0002-7768-6074
Jamil Awad Shibli https://orcid.org/0000-0003-1971-0195
Maciej Misiołek https://orcid.org/0000-0002-8476-9153
Octavi Camps-Font https://orcid.org/0000-0001-9991-2226
Akira Aoki https://orcid.org/0000-0002-2504-2894
Umberto Romeo https://orcid.org/0000-0003-2439-2187
Samir Nammour https://orcid.org/0000-0003-0321-9764

References

1. Dunn LA, Ho AL, Pfister DG. Head and neck cancer: A review. *JAMA*. 2026;335(6):531–541. doi:10.1001/jama.2025.21733
2. Villa A, Lodolo M, Ha P. Oncological outcomes of patients with oral potentially malignant disorders. *JAMA Otolaryngol Head Neck Surg*. 2025;151(1):65–71. doi:10.1001/jamaoto.2024.3719
3. Iocca O, Sollecito TP, Alawi F, et al. Potentially malignant disorders of the oral cavity and oral dysplasia: A systematic review and meta-analysis of malignant transformation rate by subtype. *Head Neck*. 2020;42(3):539–555. doi:10.1002/hed.26006
4. Mello FW, Miguel AFP, Dutra KL, et al. Prevalence of oral potentially malignant disorders: A systematic review and meta-analysis. *J Oral Pathol Med*. 2018;47(7):633–640. doi:10.1111/jop.12726
5. Khodadadi M, Khodadadi M. Malignant transformation rate of oral precancerous disorders to oral cancer: Systematic review and meta-analysis of the current evidence. *Front Oral Health*. 2025;6:1673474. doi:10.3389/froh.2025.1673474
6. Pimenta-Barros LA, Ramos-García P, González-Moles MÁ, Aguirre-Urizar JM, Warnakulasuriya S. Malignant transformation of oral leukoplakia: Systematic review and comprehensive meta-analysis. *Oral Dis*. 2025;31(1):69–80. doi:10.1111/odi.15140
7. Fatih MT, Mahmood MK, Garib BT, et al. Malignant transformation of oral leukoplakia and proliferative verrucous leukoplakia and its biomarker predictors: A systematic umbrella review. *Head Neck*. 2026;48(1):246–260. doi:10.1002/hed.70073
8. Lodolo M, Valor J, Villa A. Randomized controlled trials for oral leukoplakia. *Oral Dis*. 2025;31(11):3034–3038. doi:10.1111/odi.15399
9. Gates JC, Abouyared M, Shnayder Y, et al. Clinical management update of oral leukoplakia: A review from the American Head and Neck Society Cancer Prevention Service. *Head Neck*. 2025;47(2):733–741. doi:10.1002/hed.28013
10. Lodi G, Franchini R, Warnakulasuriya S, et al. Interventions for treating oral leukoplakia to prevent oral cancer. *Cochrane Database Syst Rev*. 2016;7(7):CD001829. doi:10.1002/14651858.CD001829.pub4
11. Pentenero M, Sutera S, Lodi G, Bagan JV, Farah CS. Oral leukoplakia diagnosis and treatment in Europe and Australia: Oral medicine practitioners' attitudes and practice. *Oral Dis*. 2023;29(8):3214–3222. doi:10.1111/odi.14301
12. de Pauli Paglioni M, Migliorati CA, Schausltz Pereira Faustino I, et al. Laser excision of oral leukoplakia: Does it affect recurrence and malignant transformation? A systematic review and meta-analysis. *Oral Oncol*. 2020;109:104850. doi:10.1016/j.oraloncology.2020.104850
13. Datarkar A, Shah V, Pandilwar P, Daware S, Datarkar S, Godase P. Is CO_2 laser effective in the surgical management of oral potentially malignant disorders? A systematic review and meta-analysis. *Lasers Med Sci*. 2025;40(1):132. doi:10.1007/s10103-025-04396-w
14. de Arruda JAA, Silva LVDO, Kato CDNAO, et al. Management of oral leukoplakia with an 808-nm high-power diode laser: A single-center experience. *Lasers Med Sci*. 2023;38(1):141. doi:10.1007/s10103-023-03806-1
15. Nammour S, Zeinoun T, Namour A, Vanheusden A, Vescovi P. Evaluation of different laser-supported surgical protocols for the treatment of oral leukoplakia: A long-term follow-up. *Photomed Laser Surg*. 2017;35(11):629–638. doi:10.1089/pho.2016.4256
16. Grzech-Leśniak K. Lasers in dentistry – overview based on FDI policy statement. *Int Dent J*. 2026;76(2):109369. doi:10.1016/j.identj.2025.109369
17. Palaia G, Bellisario A, Pampena R, Pippi R, Romeo U. Oral proliferative verrucous leukoplakia: Progression to malignancy and clinical implications. Systematic review and meta-analysis. *Cancers (Basel)*. 2021;13(16):4085. doi:10.3390/cancers13164085
18. Parker S, Grzech-Leśniak K, Cronshaw M, Matys J, Brugnera AJ, Nammour S. Full operating parameter recording as an essential component of the reproducibility of laser-tissue interaction and treatments. *Adv Clin Exp Med*. 2024;33(6):653–656. doi:10.17219/acem/189795
19. Aromataris E, Stern C, Lockwood C, et al. JBI series paper 2: Tailored evidence synthesis approaches are required to answer diverse questions: A pragmatic evidence synthesis toolkit from JBI. *J Clin Epidemiol*. 2022;150:196–202. doi:10.1016/j.jclinepi.2022.04.006
20. Page MJ, McKenzie JE, Bossuyt PM, et al. The PRISMA 2020 statement: An updated guideline for reporting systematic reviews. *BMJ*. 2021;372:n71. doi:10.1136/bmj.n71
21. Higgins JPT, Thomas J, Chandler J, et al. *Cochrane Handbook for Systematic Reviews of Interventions*. Hoboken, USA: John Wiley & Sons; 2019. doi:10.1002/9781119536604
22. Eriksen MB, Frandsen TF. The impact of patient, intervention, comparison, outcome (PICO) as a search strategy tool on literature search quality: A systematic review. *J Med Libr Assoc*. 2018;106(4):420–431. doi:10.5195/jmla.2018.345
23. Bhattarai BP, Singh AK, Singh RP, et al. Recurrence in oral leukoplakia: A systematic review and meta-analysis. *J Dent Res*. 2024;103(11):1066–1075. doi:10.1177/00220345241266519
24. Gondivkar SM, Gadbail AR, Choudhary MG, Vedpathak PR, Likhitkar MS. Photodynamic treatment outcomes of potentially-malignant lesions and malignancies of the head and neck region: A systematic review. *J Invest Clin Dent*. 2018;9(1). doi:10.1111/jicd.12270
25. Luo R, Wang Y, Li R, et al. Laser therapy decreases oral leukoplakia recurrence and boosts patient comfort: A network meta-analysis and systematic review. *BMC Oral Health*. 2024;24(1):469. doi:10.1186/s12903-024-04179-9
26. Proaño-Haro A, Bagan L, Bagan JV. Recurrences following treatment of proliferative verrucous leukoplakia: A systematic review and meta-analysis. *J Oral Pathol Med*. 2021;50(8):820–828. doi:10.1111/jop.13178
27. Abdul NS. A systematic review on the effectiveness of photodynamic therapy in the treatment of oral precancerous lesions and oral cancers. *J Pharm Bioallied Sci*. 2025;17(Suppl 4):S2862–S2866. doi:10.4103/jpbs.jpbs_1361_25
28. Dong Y, Chen Y, Tao Y, et al. Malignant transformation of oral leukoplakia treated with carbon dioxide laser: A meta-analysis. *Lasers Med Sci*. 2019;34(1):209–221. doi:10.1007/s10103-018-2674-7
29. Li Y, Wang B, Zheng S, He Y. Photodynamic therapy in the treatment of oral leukoplakia: A systematic review. *Photodiagnosis Photodyn Ther*. 2019;25:17–22. doi:10.1016/j.pdpdt.2018.10.023

30. Sattayut S, Srisilapanan P, Patcharanuchat P. Utilizing laser therapy to manage oral potentially malignant disorders in older adults at the primary care level. *Adv Clin Exp Med*. 2024;33(10):1033–1037. doi:10.17219/acem/193604
31. Mogedas-Vegara A, Hueto-Madrid JA, Chimenos-Küstner E, Bescós-Atín C. Oral leukoplakia treatment with the carbon dioxide laser: A systematic review of the literature. *J Craniomaxillofac Surg*. 2016;44(4):331–336. doi:10.1016/j.jcms.2016.01.026
32. Mogedas-Vegara A, Hueto-Madrid JA, Chimenos-Küstner E, Bescós-Atín C. The treatment of oral leukoplakia with the CO_2 laser: A retrospective study of 65 patients. *J Craniomaxillofac Surg*. 2015;43(5):677–681. doi:10.1016/j.jcms.2015.03.011
33. Ishii J, Fujita K, Komori T. Laser surgery as a treatment for oral leukoplakia. *Oral Oncol*. 2003;39(8):759–769. doi:10.1016/S1368-8375(03)00043-5
34. Ou J, Gao Y, Li H, Ling T, Xie X. Application of 5-aminolevulinic acid-mediated Waterlase-assisted photodynamic therapy in the treatment of oral leukoplakia. *Sci Rep*. 2022;12(1):9391. doi:10.1038/s41598-022-13497-3
35. Jurczyszyn K, Kozakiewicz M. Application of texture and fractal dimension analysis to estimate effectiveness of oral leukoplakia treatment using an Er:YAG laser – a prospective study. *Materials (Basel)*. 2020;13(16):3614. doi:10.3390/ma13163614
36. Schwarz F, Maraki D, Yalcinkaya S, Bieling K, Böcking A, Becker J. Cytologic and DNA-cytometric follow-up of oral leukoplakia after CO_2- and Er:YAG-laser assisted ablation: A pilot study. *Lasers Surg Med*. 2005;37(1):29–36. doi:10.1002/lsm.20188
37. Suter VGA, Altermatt HJ, Bornstein MM. A randomized controlled trial comparing surgical excisional biopsies using CO_2 laser, Er:YAG laser and scalpel. *Int J Oral Maxillofac Surg*. 2020;49(1):99–106. doi:10.1016/j.ijom.2019.05.012
38. Romanos G, Nentwig GH. Diode laser (980 nm) in oral and maxillofacial surgical procedures: Clinical observations based on clinical applications. *J Clin Laser Med Surg*. 1999;17(5):193–197. doi:10.1089/clm.1999.17.193
39. Arora KS, Bansal R, Mohapatra S, Verma A, Sharma S, Pareek S. Prevention of malignant transformation of oral leukoplakia and oral lichen planus using laser: An observational study. *Asian Pac J Cancer Prev*. 2018;19(12):3635–3641. doi:10.31557/APJCP.2018.19.12.3635
40. López-Jornet P, Camacho-Alonso F. Comparison of pain and swelling after removal of oral leukoplakia with CO_2 laser and cold knife: A randomized clinical trial. *Med Oral Patol Oral Cir Bucal*. 2013;18(1):e38–e44. doi:10.4317/medoral.17960
41. Grzech-Leśniak K, Wiench R, Shibli JA, et al. Laser therapies as the adjunctive treatment of medication-related osteonecrosis of the jaw: Evidence synthesis and clinical recommendations. Official recommendations of the World Federation for Laser Dentistry (WFLD) and the Polish Society for Laser Dentistry (PTSL) [published online as ahead of print on May 14, 2026]. *Dent Med Probl*. 2026. doi:10.17219/dmp/220709
42. Warnakulasuriya S, Kujan O, Aguirre-Urizar JM, et al. Oral potentially malignant disorders: A consensus report from an international seminar on nomenclature and classification, convened by the WHO Collaborating Centre for Oral Cancer. *Oral Dis*. 2021;27(8):1862–1880. doi:10.1111/odi.13704
43. Yao YL, Wang YF, Li CX, Wu L, Tang GY. Management of oral leukoplakia by ablative fractional laser-assisted photodynamic therapy: A 3-year retrospective study of 48 patients. *Lasers Surg Med*. 2022;54(5):682–687. doi:10.1002/lsm.23534
44. van der Hem PS, Nauta JM, van der Wal JE, Roodenburg JLN. The results of CO_2 laser surgery in patients with oral leukoplakia: A 25 year follow up. *Oral Oncol*. 2005;41(1):31–37. doi:10.1016/j.oraloncology.2004.06.010
45. Monteiro L, Barbieri C, Warnakulasuriya S, et al. Type of surgical treatment and recurrence of oral leukoplakia: A retrospective clinical study. *Med Oral Patol Oral Cir Bucal*. 2017;22(5):e520–e526. doi:10.4317/medoral.21645
46. Schoelch ML, Sekandari N, Regezi JA, Silverman S. Laser management of oral leukoplakias: A follow-up study of 70 patients. *Laryngoscope*. 1999;109(6):949–953. doi:10.1097/00005537-199906000-00021
47. Rodriguez-Lujan A, López-Jornet P, Pons-Fuster López E. Recurrence of oral leukoplakia after CO_2 laser resection: A prospective longitudinal study. *Cancers (Basel)*. 2022;14(21):5455. doi:10.3390/cancers14215455
48. Bagan J, Martorell M, Cebrián JL, et al. Effect of clinical and histologic features on time to malignancy in 224 cases of oral leukoplakia treated by surgery. *Clin Oral Investig*. 2022;26(8):5181–5188. doi:10.1007/s00784-022-04486-x
49. Tenore G, Mohsen A, Fantozzi PJ, et al. Risk assessment for malignant transformation in patients with oral proliferative leukoplakia: A 10-year retrospective cohort study. *Cancers (Basel)*. 2025;18(1):2. doi:10.3390/cancers18010002
50. Pentenero M, Meleti M, Vescovi P, Gandolfo S. Oral proliferative verrucous leucoplakia: Are there particular features for such an ambiguous entity? A systematic review. *Br J Dermatol*. 2014;170(5):1039–1047. doi:10.1111/bjd.12853
51. Lauritano D, Lucchese A, Gabrione F, Di Stasio D, Silvestre Rangil J, Carinci F. The effectiveness of laser-assisted surgical excision of leukoplakias and hyperkeratosis of oral mucosa: A case series in a group of patients. *Int J Environ Res Public Health*. 2019;16(2):210. doi:10.3390/ijerph16020210
52. Lim B, Smith A, Chandu A. Treatment of oral leukoplakia with carbon dioxide and potassium-titanyl-phosphate lasers: A comparison. *J Oral Maxillofac Surg*. 2010;68(3):597–601. doi:10.1016/j.joms.2009.03.028
53. Natekar M, Raghuveer HP, Rayapati DK, et al. A comparative evaluation: Oral leukoplakia surgical management using diode laser, CO_2 laser, and cryosurgery. *J Clin Exp Dent*. 2017;9(6):e779–e784. doi:10.4317/jced.53602
54. Kuribayashi Y, Tsushima F, Sato M, Morita K, Omura K. Recurrence patterns of oral leukoplakia after curative surgical resection: Important factors that predict the risk of recurrence and malignancy. *J Oral Pathol Med*. 2012;41(9):682–688. doi:10.1111/j.1600-0714.2012.01167.x
55. Shivhare P, Haidry N, Kumar A, Parihar A, Singh A, Subramanyam S. Diode laser in the management of leukoplakia – a retrospective study. *Ann Maxillofac Surg*. 2022;12(2):178–184. doi:10.4103/ams.ams_117_22
56. Vilar-Villanueva M, Somoza-Martín JM, Blanco-Carrión A, et al. Importance of the vaporization margin during CO_2 laser treatment of oral leukoplakia: A survival study. *Oral Dis*. 2023;29(7):2689–2695. doi:10.1111/odi.14345
57. Dutra MJ, Araujo IS, Wagner VP, et al. Management of surgical margins in the excision of oral leukoplakia: A scoping review. *Oral Dis*. 2026;32(7):1748–1755. doi:10.1111/odi.70231
58. Vu J, Coleman HG, Palme CE, Riffat F, Schifter M, Zoellner H. Diagnostic utility of microsurgical carbon dioxide laser excision of oral potentially malignant lesions vs incisional biopsy: A retrospective histopathological review. *Oral Surg Oral Med Oral Pathol Oral Radiol*. 2019;127(6):516–525. doi:10.1016/j.oooo.2018.12.010
59. Vivek V, Jayasree RS, Balan A, Sreelatha KT, Gupta AK. Three-year follow-up of oral leukoplakia after neodymium:yttrium aluminum garnet (Nd:YAG) laser surgery. *Lasers Med Sci*. 2008;23(4):375–379. doi:10.1007/s10103-007-0500-8
60. Sagalow ES, Kumar AT, Banoub RG, et al. Recurrence of premalignant oral cavity and oropharynx lesions after pulsed diode laser treatment. *Am J Otolaryngol*. 2022;43(5):103556. doi:10.1016/j.amjoto.2022.103556
61. Romeo U, Mohsen M, Palaia G, Bellisario A, Del Vecchio A, Tenore G. CO_2 laser ablation of oral leukoplakia: With or without extension of margins? *Clin Ter*. 2020;171(3):e209–e215. doi:10.7417/CT.2020.2215
62. Vescovi P, Corcione L, Meleti M, et al. Nd:YAG laser versus traditional scalpel. A preliminary histological analysis of specimens from the human oral mucosa. *Lasers Med Sci*. 2010;25(5):685–691. doi:10.1007/s10103-010-0770-4
63. Merigo E, Clini F, Fornaini C, et al. Laser-assisted surgery with different wavelengths: A preliminary ex vivo study on thermal increase and histological evaluation. *Lasers Med Sci*. 2013;28(2):497–504. doi:10.1007/s10103-012-1081-8
64. Pergolini D, Del Vecchio A, Mohsen M, et al. Histological evaluation of oral soft tissue biopsy by dual-wavelength diode laser: An ex vivo study. *Dent J (Basel)*. 2025;13(6):265. doi:10.3390/dj13060265

65. Palaia G, Renzi F, Pergolini D, et al. Histological ex vivo evaluation of the suitability of a 976 nm diode laser in oral soft tissue biopsies. *Int J Dent*. 2021;2021:6658268. doi:10.1155/2021/6658268
66. Yang SW, Lee YS, Chang LC, Yang CH, Luo CM, Wu PW. Oral tongue leukoplakia: Analysis of clinicopathological characteristics, treatment outcomes, and factors related to recurrence and malignant transformation. *Clin Oral Investig*. 2021;25(6):4045–4058. doi:10.1007/s00784-020-03735-1
67. Rashid A, Warnakulasuriya S. The use of light-based (optical) detection systems as adjuncts in the detection of oral cancer and oral potentially malignant disorders: A systematic review. *J Oral Pathol Med*. 2015;44(5):307–328. doi:10.1111/jop.12218