Original paper

Incidental detection of carotid artery calcification on CBCT: A retrospective analysis of 890 scans (108 cases)

Walla Samara[1,A,D,E], Omid Moztarzadeh[1,2,A,E,F], Mohammad Najeh Samara[3,A,C], Lukas Hauer[1,E,F], Jan Pernicky[2,4,B,C]

[1] Department of Stomatology, University Hospital Pilsen, Faculty of Medicine in Pilsen, Charles University, Pilsen, Czech Republic
[2] Department of Anatomy, Faculty of Medicine in Pilsen, Charles University, Pilsen, Czech Republic
[3] Department of Systems Science and Industrial Engineering, State University of New York at Binghamton, USA
[4] Department of Imaging Methods, University Hospital Pilsen, Faculty of Medicine in Pilsen, Charles University, Pilsen, Czech Republic

A – research concept and design; B – collection and/or assembly of data; C – data analysis and interpretation;
D – writing the article; E – critical revision of the article; F – final approval of the article

Dental and Medical Problems, ISSN 1644-387X (print), ISSN 2300-9020 (online) *Dent Med Probl*. 2026;63(5):1215–1224

Address for correspondence
Omid Moztarzadeh
E-mail: omid.moztarzadeh@lfp.cuni.cz

Funding sources
None declared

Conflict of interest
None declared

Acknowledgements
None declared

Received on August 17, 2025
Reviewed on September 9, 2025
Accepted on October 10, 2025

Published online on October 6, 2026

Abstract

Background. Carotid artery calcifications (CACs) are markers of atherosclerosis and an increased risk of stroke. Therefore, their incidental detection on dental cone beam computed tomography (CBCT) scans can be clinically relevant. Early detection allows timely intervention, potentially reducing the risk of serious cerebral and cardiovascular complications.

Objectives. The aim of the study was to retrospectively analyze the prevalence and severity of CACs on CBCT images and their association with patient characteristics and various risk factors.

Material and methods. This retrospective study evaluated 890 CBCT examinations. Of these, 108 patients exhibiting sclerotic changes in the internal carotid artery (ICA) were included and classified as mild, moderate or severe based on the severity of calcification. The study excluded individuals younger than 50 years, as well as cases in which similar radiopacities could not be clearly differentiated. The associations between various clinical variables, including lipid profile parameters, smoking status, a history of chronic diseases, and the severity of calcifications were statistically analyzed.

Results. A total of 108 patients were categorized based on the severity of calcification as mild ($n = 53$), moderate ($n = 41$) or severe ($n = 14$). The findings indicated significant associations between CAC severity and age ($p < 0.001$), low-density lipoprotein (LDL) levels ($p < 0.001$), triglyceride levels (TAG) ($p = 0.002$), and hypertension ($p = 0.027$). Low-density lipoprotein levels demonstrated the strongest correlation with the severity of stenosis ($p = 0.102$).

Conclusions. Cone beam computed tomography may incidentally reveal CACs, highlighting the potential need for further medical evaluation. Larger studies are required to confirm the clinical significance of these findings.

Keywords: cone-beam computed tomography, carotid artery atherosclerosis, vascular incidental findings, calcifications

Cite as
Samara W, Moztarzadeh O, Samara MN, Hauer L, Pernicky J. Incidental detection of carotid artery calcification on CBCT: A retrospective analysis of 890 scans (108 cases). *Dent Med Probl*. 2026;63(5):1215–1224. doi:10.17219/dmp/211938

DOI
10.17219/dmp/211938

Copyright
Copyright by Author(s)
This is an article distributed under the terms of the Creative Commons Attribution 3.0 Unported (CC BY 3.0) (https://creativecommons.org/licenses/by/3.0/)

Highlights

- Cone beam computed tomography (CBCT) can incidentally detect carotid artery calcifications (CACs) during routine dental imaging, providing an opportunity for early detection of vascular disease.
- Recognizing incidental CACs may allow dentists to guide patients for timely medical evaluation and stroke prevention.
- This retrospective analysis demonstrates a measurable prevalence of CACs across different risk groups.
- Carotid artery calcifications were detected in 108 patients over 50 years of age, including 14 individuals with severe calcifications.
- Chronic cardiovascular risk factors were associated with CACs, with the strongest correlation observed between CACs and elevated low-density lipoprotein levels.

Introduction

Atherosclerosis is a chronic disease characterized by the buildup of lipid-rich plaques in the arterial walls, leading to intimal fibrosis, necrosis, vessel narrowing, and potential stenosis. It can result in vessel stiffening, hemodynamic disturbances, and acute occlusion due to plaque rupture, which may cause serious secondary conditions such as heart attacks and strokes.[1] Atherosclerosis is the primary contributor to cardiovascular and cerebrovascular diseases, which remain the leading causes of mortality and morbidity worldwide, affecting large and medium-sized arteries. It tends to develop at arterial bends or bifurcations, where there is decreased endothelial shear stress or disrupted blood flow. The impact of atherosclerosis varies depending on its location, such as the coronary arteries, where it may lead to coronary artery syndrome, or the carotid and intracranial arteries, where it may result in stroke or transient ischemic attack (TIA).[2]

Vascular calcifications are present in 80–90% of atheromas and are recognized as both a sign of aging and an active, self-regulating process involving complex cellular and enzymatic mechanisms. Calcification can occur in the medial and intimal layers of blood vessels, including the intracranial and cervical carotid arteries, and contribute to the formation of atheromatous plaques. These plaques can narrow or block blood vessels, potentially resulting in serious health issues such as carotid artery stenosis (CAS), ischemic stroke, vision loss, and an overall increase in morbidity and mortality.[3] Carotid artery calcifications (CACs), seen as radiopacities in the cervical region, are known as extracranial carotid calcifications, while those along the internal carotid artery (ICA) within the cranium are referred to as intracranial carotid calcifications. Various methods, such as computed tomography (CT), magnetic resonance imaging (MRI) and angiography, are used to detect and assess these calcifications. The occurrence and frequency of CACs differ according to sex, age, genetic predisposition, and lifestyle-related risk factors and comorbidities.[4]

Carotid artery stenosis is a frequently encountered condition in routine medical practice. It is a significant cause of acute ischemic stroke, accounting for around 20% of cases. Carotid artery stenosis can be categorized as either symptomatic or asymptomatic, with this distinction greatly influencing the treatment approach. Symptomatic disease may present as acute neurological ischemia or amaurosis fugax, requiring immediate vascular or emergency evaluation. Conversely, asymptomatic disease may be identified after detecting a carotid bruit or incidentally during imaging.[5] Panoramic radiographs commonly used in dental practice can incidentally reveal CACs as irregular, nodular opacities near the mandibular angle at the C3–C4 vertebral levels.[6] Due to the widespread use of panoramic radiography in routine dental care, dental professionals are well-positioned to detect signs of CAC. This situates them as potential frontline contributors to cardiovascular risk screening, enabling timely identification and appropriate referral for further medical assessment.[7,8] Radiographic examination plays an important role in dentistry, and the detection of carotid artery atheromas on panoramic radiographs may facilitate the prevention of cerebrovascular events, although general practitioners may have limited diagnostic expertise in this area. Advances in cone beam computed tomography (CBCT) allow for detailed three-dimensional (3D) imaging, improving diagnostic accuracy and dental treatment planning. Cone beam computed tomography, with its wide cone-shaped X-ray beam, enables evaluation of the carotid artery bifurcation at the epiglottis level, in relation to the C3 and C4 vertebrae and the upper thyroid cartilage.[9]

Cone beam computed tomography is becoming increasingly significant due to its accurate multiplanar imaging, which is crucial for thorough structural assessments. The technique enables adjustment of the field of view (FOV) according to the specific requirements of the examination. Smaller FOVs concentrate on the maxillofacial complex, while larger volumes can capture the sinuses and other craniofacial structures. Progress in CBCT technology, improved image quality, heightened awareness of medicolegal issues, and increasing expertise among practitioners have resulted in more incidental findings during 3D evaluations. However, standardized protocols for managing these unexpected outcomes remain limited.[10] Unlike traditional two-dimensional (2D) radiography, CBCT provides volumetric data, allowing visualization of anatomical structures in all

dimensions. As a result, clinicians can identify pathologies that fall outside the primary region of interest, including those affecting anatomically significant areas.[11] Beyond its role in diagnostic imaging, CBCT is increasingly applied to clinical decision-making, such as for the evaluation of sagittal root position for immediate implant placement in the anterior maxilla. The versatility of CBCT is also evident in emerging diagnostic applications, such as the use of pulp chamber volume to estimate chronological age in teeth with open apices.[12,13]

An incidental radiographic finding refers to any discovery made by diagnostic imaging techniques such as CT or CBCT that is unrelated to the original reason for conducting the assessment. When examining CBCT scans, it is crucial for medical professionals to analyze the entire image volume instead of focusing solely on the area of interest. Thorough and methodical assessment enables the identification of incidental findings of potential clinical significance.[14] In recent years, artificial intelligence (AI) has gained attention as a tool for detecting CACs in dental imaging. A systematic review by Arzani et al. highlighted the growing potential of AI-based methods for identifying CACs on dental radiographs.[15] Yoo et al. developed CACSNet, a deep learning model capable of automatically classifying and segmenting CACs on panoramic radiographs.[16] While these advances are promising, most focus on 2D imaging, and volumetric CBCT-based assessment with vascular correlation remains limited.[15,16]

Missed lesions are the leading cause of malpractice in radiology, raising concerns for clinicians due to the frequent occurrence of incidental findings in CBCT scans. These findings may involve either skeletal structures or soft tissues; however, soft tissues may not be clearly visible due to CBCT's limited contrast resolution. Therefore, clinicians who use CBCT must have a comprehensive understanding of head and neck anatomy, along with an awareness of the occurrence of pathological abnormalities and false-positive results in CBCT examinations.[17] The aim of the present study was to retrospectively evaluate the role of CBCT in the early detection of CACs as incidental findings.

Material and methods

Study sample selection

The protocol of the study was approved by the Ethics Committee of the University Hospital and the Faculty of Medicine in Pilsen, Charles University (reference No. 93/25).

Cone beam computed tomography examinations of 890 patients performed between January 2023 and December 2024 at the Stomatology Department of the University Hospital Pilsen (Czech Republic) were retrospectively reviewed. Of these, 108 CBCT scans obtained from patients aged over 50 years with identified CACs were included in the study. All scans were acquired using the maxillofacial protocol mode, either with a full-volume or large FOV setting, to ensure comprehensive imaging of the anatomical area of interest.

Exclusion criteria included patients under 50 years of age, scans with significant motion artifacts or metallic fixation that could obscure the area being evaluated, and cases with other potential sources of calcification. For each included case, the patient's age and sex were recorded. When available, data on lipid profile parameters (low-density lipoprotein (LDL), high-density lipoprotein (HDL) and triglycerides (TAG)) was also retrieved from routine clinical records obtained within 6 months before or 3 months after the CBCT scan. Laboratory values were linked to imaging findings and compiled into a de-identified dataset for analysis. Smoking status, history of cardiovascular disease, coagulation disorders, hypertension, diabetes, and the use of anticoagulant therapy were also recorded.

An experienced radiologist evaluated the CBCT scans and categorized the patients into 3 groups based on the severity of atherosclerotic changes: mild; moderate; and severe. The associations between various demographic and clinical variables and the severity of calcification were statistically analyzed. Furthermore, we investigated the relationship between patient characteristics and the degree of CAS in patients with severe calcifications, as assessed by CT angiography.

Imaging procedure

The examinations were performed using the KaVo OP 3D Vision device (KaVo Dental, Biberach, Germany). The FOV of the scans ranged from 150 mm × 150 mm to 160 mm × 100 mm. Of the 108 patients, 68 underwent CBCT with an FOV of 150 mm × 150 mm, 5 with an FOV of 160 mm × 130 mm, and 35 with an FOV of 160 mm × 100 mm. The voxel size ranged from 0.6 mm to 0.3 mm, with a scan time of 10–18 s depending on the selected resolution. The radiation dose was determined based on the slice thickness – for 0.6 mm, the reported dose was 80–100 mGy/cm^2, whereas for 0.3 mm, it was approx. 300 Gy/cm^2. Radiation dose values were obtained from the metrics reported by the device. Effective dose and dose–area product (DAP) values were not available for retrospective extraction and thus could not be consistently reported.

The most commonly used slice thickness was 0.3 mm. Both CBCT and CT examinations were radiologically analyzed using syngo.via for CT software (Siemens Healthineers, Erlangen, Germany). A total of 108 CBCT images from patients referred for various dental indications, primarily implant planning or third molar assessment, were analyzed. Although the primary indication for imaging was purely dental, the scan volume incidentally included the cervical spine (C3–C4) and extracranial ICA region, allowing the detection of CACs. The scans were evaluated by an experienced radiologist with 9 years of professional experience.

Assessment of findings

A total of 108 CBCT examinations in which CACs were identified in the extracranial segment of the ICA region were selected for analysis. Calcifications were confirmed as carotid in origin only if they were visible in at least 3 consecutive axial slices and aligned with the known anatomical course of the ICA (lateral to the pharyngeal wall, adjacent to the C3–C4 vertebral level, and medial to the styloid process). Calcifications in the tonsillar region and other sources of radiopacity (e.g., tonsilloliths, calcified triticeous cartilage, stylohyoid ligament ossification, and lymph node calcifications) were excluded based on their distinct morphology and anatomical position on multiplanar CBCT reconstructions. Further evaluation was conducted by an experienced radiologist using syngo.via for CT software.

The classification was based on a predefined visual scale introduced by Fisher et al. to estimate the severity of atherosclerosis.[18] The grading was performed on axial reconstructions at the level of the extracranial segment of the ICA (segment C1), using bony and cartilaginous landmarks for localization. The severity categories were defined as follows:

– mild: sclerotic changes are slight, thin or discontinuous, without evidence of plaque thickening;
– moderate: sclerotic changes are wider and may be continuous, following the course of the ICA;
– severe: sclerotic changes are thick, irregular and continuous, consistent with a densely calcified atheromatous plaque.

Statistical analysis

All statistical analyses were performed using Python programming language with appropriate statistical packages, including SciPy, NumPy and Pandas. This study employed a two-tier analytical approach reflecting the hierarchical nature of the data collection: a primary analysis of all patients with CBCT-detected calcifications (n = 108); and a secondary analysis of the subset with severe calcifications confirmed by CT angiography (n = 14).

Primary analysis: CAC severity

This analysis included 108 patients, identified among 890 CBCT examinations, who had detectable CACs and were categorized as having mild, moderate or severe calcifications. Parametric and non-parametric tests were applied for the analysis of associations between patient characteristics and CAC severity, according to the distribution of data:

– continuous variables (age, LDL cholesterol, HDL cholesterol, and TAG): one-way analysis of variance (ANOVA) was used to compare mean values across the 3 calcification severity groups (mild, moderate and severe) for normally distributed continuous variables. Post hoc analyses were performed where appropriate to identify specific between-group differences;
– categorical variables (sex, smoking status, diabetes, hypertension, coagulation disorders, and cardiovascular disease): χ^2 test of independence was employed for categorical variables with adequate expected cell frequencies. Fisher's exact test was used when expected cell frequencies were insufficient, ensuring robust analysis despite small cell counts in some categories.

Secondary analysis: CT angiography stenosis subset

This analysis focused exclusively on the 14 patients with severe calcifications who underwent confirmatory CT angiography. Given the limited sample size, which provided approx. 30% power to detect large effect sizes, non-parametric tests were employed to avoid distributional assumptions. These findings should be interpreted as exploratory and hypothesis-generating rather than confirmatory, as the small sample size limits the ability to detect statistically significant associations even when meaningful trends may exist. Given the small sample size, the following non-parametric tests were applied for the analysis of associations between patient characteristics and the percentage of CAS measured by CT angiography, regardless of data distribution:

– continuous variables (age, LDL cholesterol, HDL cholesterol, and TAG): Spearman's rank correlation coefficient (rho). This non-parametric correlation method was chosen because it does not assume linearity or normality of data distribution;
– categorical variables (sex, smoking status, diabetes status, hypertension, antihypertensive therapy, cardiovascular disease, coagulation disorders, anticoagulant use, and antidiabetic medication use): Mann–Whitney U test was used to compare percentages of stenosis between two-group categorical variables;
– comparative analysis: Spearman's correlation was used to examine the relationship between CT angiography and ultrasound measurements. Pearson's correlation coefficient (r) was additionally reported for comparison.

Interpretation of statistical findings

For the primary analysis (n = 108), we conducted 10 statistical comparisons: age; sex; smoking status; diabetes; hypertension; coagulation disorders; cardiovascular disease; LDL cholesterol; HDL cholesterol; and TAG. To control for type I error inflation due to multiple testing, a Bonferroni correction was applied (adjusted α = 0.05/10 = 0.005). Variables with p-values <0.005 were considered statistically significant after correction. We report both unadjusted and Bonferroni-adjusted significance levels in the results. For the secondary analysis (n = 14), results are presented as exploratory findings with unadjusted p-values,

acknowledging the limited statistical power. For the secondary analysis, a *p*-value <0.05 (unadjusted) was considered statistically significant. Results are presented as mean ± standard deviation (*M* ±*SD*) for continuous variables and as frequencies with percentages for categorical variables. All findings from the CT angiography subset should be interpreted as hypothesis-generating rather than confirmatory due to the limited sample size.

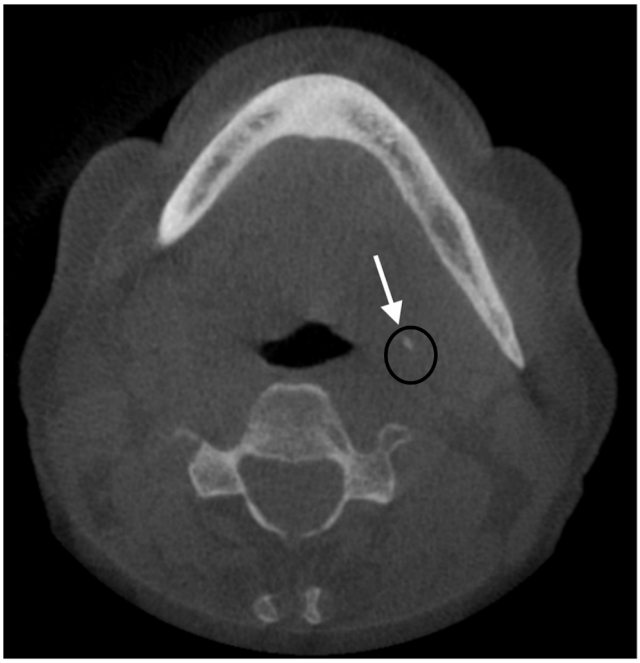

Fig. 1. Axial cone beam computed tomography (CBCT) image showing a midly calcified lesion (white arrow)

The lesion is thin, hairline-like and discontinuous.

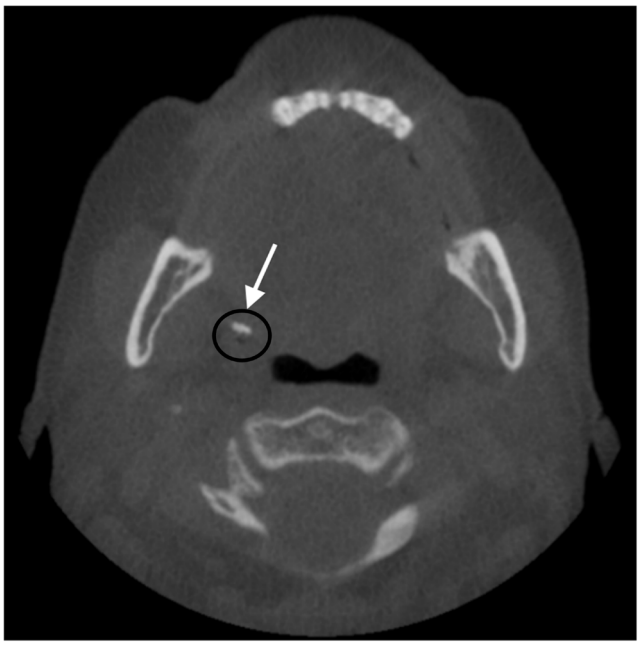

Fig. 2. Axial cone beam computed tomography (CBCT) image showing a moderately calcified lesion (white arrow)

The lesion is wider and slightly coarser and may be continuous.

Results

Of the 890 CBCT examinations performed between January 2023 and December 2024, CACs were identified in 108 patients (12.1%). These calcifications were classified as mild (*n* = 53, 49.1%), moderate (*n* = 41, 38.0%) or severe (*n* = 14, 13.0%) (Fig. 1–3). All 14 patients with severe CACs underwent confirmatory vascular imaging: 3 initially underwent Doppler ultrasonography (Fig. 4) followed by CT angiography (Fig. 5), while 11 proceeded directly to CT angiography. The study population (*N* = 108) included 53.7% of women and 46.3% of men, all of whom were over 50 years of age.

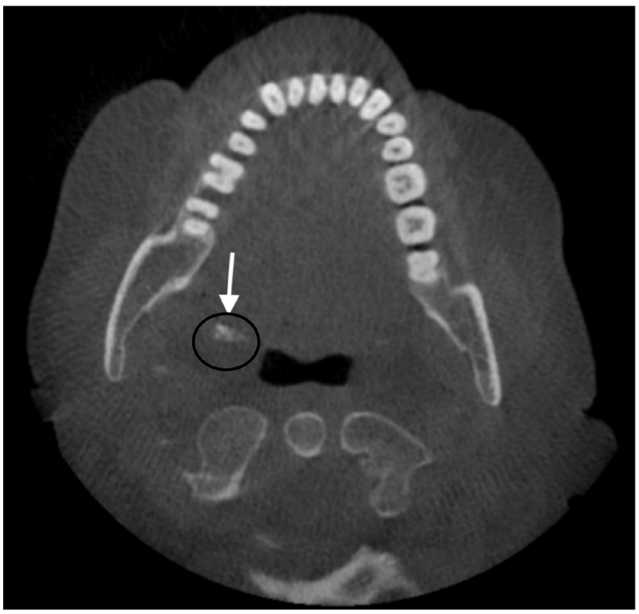

Fig. 3. Axial cone beam computed tomography (CBCT) image showing a severely calcified lesion (white arrow)

The lesion is continuous, wide, thick, and irregular.

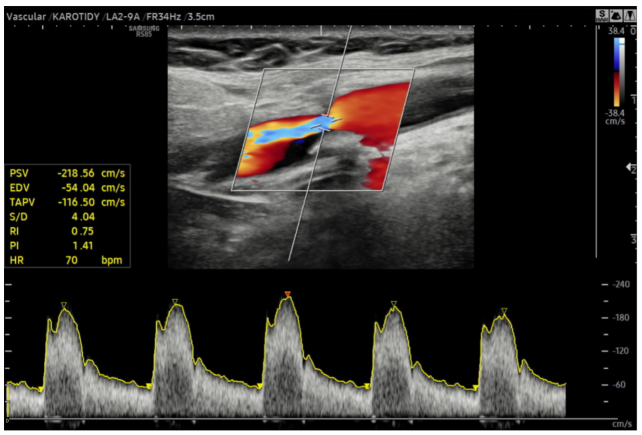

Fig. 4. Doppler ultrasonography of one of the examined patients

The image shows a longitudinal view of the internal carotid artery (ICA) with a rough atherosclerotic plaque and a maximum systolic velocity of 218 cm/s, corresponding to approx. 60–70% stenosis. The degree of stenosis was further confirmed by computed tomography (CT) angiography.
PSV – peak systolic velocity; EDV – end-diastolic velocity; TAPV – time-averaged peak velocity; S/D – systolic/diastolic ratio; RI – resistive index; PI – pulsatility index; HR – heart rate.

Analysis of CAC severity in relation to patient characteristics

Analysis of the 108 patients revealed significant associations between calcification severity and several cardiovascular risk factors (Table 1). Age showed the strongest association ($p < 0.001$), with mean age increasing progressively across the mild (60.8 ±7.4 years), moderate (65.2 ±7.5 years) and severe (73.9 ±5.1 years) groups. Lipid abnormalities were also strongly correlated with severity. High LDL cholesterol was significantly associated with more severe disease ($p < 0.001$), with 87.0% of patients with high LDL levels presenting with moderate or severe calcifications compared with 24.2% of patients with low LDL levels. Elevated TAG similarly showed a significant association ($p < 0.001$ for TAG category; $p = 0.002$ for TAG as a continuous variable), with severe calcifications observed in 26.1% of patients with high TAG vs. 3.2% of those with normal levels. Hypertension was associated with disease severity ($p = 0.027$), and severe condition was observed in 22.2% of hypertensive patients and 6.5% of normotensive patients.

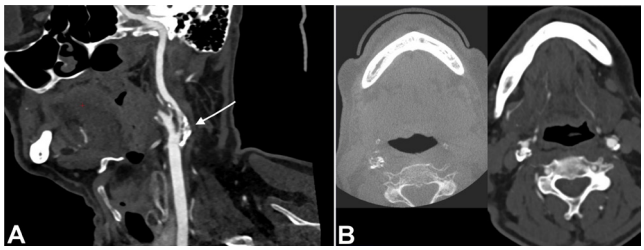

Fig. 5. Computed tomography (CT) angiography and cone beam computed tomography (CBCT) findings

A. CT angiography of the neck and brain arteries showing a longitudinal view of the common carotid artery (CCA) and internal carotid artery (ICA). The arrow indicates an extensive atherosclerotic lesion causing significant narrowing of the ICA; B. Comparison of CBCT and CT angiography findings at the corresponding axial level in the same patient.

After Bonferroni correction for multiple testing (adjusted $\alpha = 0.005$), age, LDL cholesterol and TAG remained statistically significant. Hypertension no longer reached statistical significance after correction, suggesting that this correlation should be interpreted with caution. No significant associations were found with sex, smoking, diabetes, coagulation disorders, or a history of cardiovascular disease. High-density lipoprotein cholesterol approached significance at $p = 0.051$.

Table 1. Association between patient characteristics and the severity of carotid artery calcification (CAC)

Variable		Mild ($n = 53$)	Moderate ($n = 41$)	Severe ($n = 14$)	Total ($N = 108$)	p-value
Sex, *n* (%)	male	25 (50.0)	21 (42.0)	4 (8.0)	50 (46.3)	0.335
	female	28 (48.3)	20 (34.5)	10 (17.2)	58 (53.7)	
Age [years] *M* ±*SD*		60.8 ±7.4	65.2 ±7.5	73.9 ±5.1	64.2 ±8.3	<0.001†
Smoking, *n* (%)	no	38 (52.8)	26 (36.1)	8 (11.1)	72 (66.7)	0.504
	yes	15 (42.9)	15 (42.9)	5 (14.3)	35 (32.4)	
Diabetes, *n* (%)	no	46 (51.7)	33 (37.1)	10 (11.2)	89 (82.4)	0.373
	yes	7 (36.8)	8 (42.1)	4 (21.1)	19 (17.6)	
Hypertension, *n* (%)	yes	17 (37.8)	18 (40.0)	10 (22.2)	45 (41.7)	0.027*
	no	36 (58.1)	22 (35.5)	4 (6.5)	62 (57.4)	
Coagulation disorder, *n* (%)	no	50 (50.5)	37 (37.4)	12 (12.1)	99 (91.7)	0.534
	yes	3 (33.3)	4 (44.4)	2 (22.2)	9 (8.3)	
LDL [mmol/L] *M* ±*SD*		3.08 ±0.56	3.64 ±0.63	4.29 ±0.48	3.45 ±0.71	<0.001†
LDL category, *n* (%)	high	6 (13.0)	27 (58.7)	13 (28.3)	46 (42.6)	<0.001†
	low	47 (75.8)	14 (22.6)	1 (1.6)	62 (57.4)	
HDL [mmol/L] *M* ±*SD*		1.19 ±0.22	1.20 ±0.31	1.01 ±0.26	1.17 ±0.27	0.051
HDL category, *n* (%)	high	21 (46.7)	19 (42.2)	5 (11.1)	45 (41.7)	0.718
	low	32 (50.8)	22 (34.9)	9 (14.3)	63 (58.3)	
TAG [mmol/L] *M* ±*SD*		1.72 ±0.44	1.81 ±0.44	2.21 ±0.43	1.82 ±0.46	0.002†
TAG category, *n* (%)	low	39 (62.9)	21 (33.9)	2 (3.2)	62 (57.4)	<0.001†
	high	14 (30.4)	20 (43.5)	12 (26.1)	46 (42.6)	
Cardiovascular disease, *n* (%)	yes	10 (45.5)	8 (36.4)	4 (18.2)	22 (20.4)	0.714
	no	43 (50.0)	33 (38.4)	10 (11.6)	86 (79.6)	

Continuous variables were compared using one-way analysis of variance (ANOVA); categorical variables were compared using the χ^2 test of independence or Fisher's exact test where expected cell frequencies were insufficient. Hypertension status was unavailable for 1 patient.
* statistically significant ($p < 0.05$ (unadjusted)); † statistically significant ($p < 0.005$, after Bonferroni correction); LDL – low-density lipoprotein; HDL – high-density lipoprotein; TAG – triglycerides; *M* – mean; *SD* – standard deviation.

Association between patient characteristics and the degree of carotid artery stenosis on CT angiography

This exploratory analysis examined the 14 patients with severe calcifications who underwent confirmatory CT angiography. Given the limited sample size, these findings should be interpreted cautiously as hypothesis-generating rather than definitive. We investigated the relationship between patient characteristics and the degree of stenosis as measured by CT angiography. This subset had a mean age of 73.9 years and was predominantly female (n = 10, 71.4%) (Table 2,3).

Categorical variables vs. stenosis

As shown in Table 2, none of the examined categorical variables demonstrated statistically significant associations with the percentage of stenosis measured on CT angiography. The relationship between coagulation disorder status and the percentage of stenosis approached but did not reach statistical significance (U = 23.00, p = 0.052). Patients without coagulation disorders exhibited higher mean stenosis values (73.75%) compared to those with coagulation disorders (57.50%); however, this difference was not statistically significant and should be interpreted with caution given the small sample size. Among the other categorical variables, smokers had higher mean percentages of stenosis (75.00%) than non-smokers (72.08%), and patients with diabetes showed higher stenosis values (75.00%) compared to non-diabetic individuals (70.00%). However, these differences did not reach statistical significance (p = 0.226 and p = 0.430, respectively).

Continuous variables vs. stenosis

Table 3 presents the correlations between continuous variables and the percentage of stenosis. Low-density lipoprotein levels showed the strongest correlation with

Table 2. Association between categorical patient characteristics and the percentage of carotid artery stenosis (CAS) on computed tomography (CT) angiography

Characteristic			Patients, *n*	Carotid artery stenosis [%] *M* ±*SD*	Mann–Whitney *U*	*p*-value
Demographic factors	sex	male	4	71.25 ±5.06	17.00	0.720
		female	10	71.50 ±9.54		
Cardiovascular risk factors	smoking	no	6	72.08 ±7.91	2.98	0.226
		yes	5	75.00 ±7.53		
	hypertension	yes	10	71.50 ±9.93	23.00	0.720
		no	4	71.25 ±2.50		
	antihypertensive therapy	no	5	72.00 ±3.54	21.00	0.892
		yes	9	71.11 ±10.24		
	cardiovascular disease	no	10	71.00 ±9.31	21.00	0.943
		yes	4	72.50 ±5.00		
Coagulation parameters	coagulation disorder	no	12	73.75 ±5.63	23.00	0.052
		yes	2	57.50 ±10.61		
	anticoagulant use	no	13	71.92 ±8.00	11.00	0.314
		yes	1	65.00 (*SD* not applicable)		
Metabolic factors	diabetes	no	10	70.00 ±8.50	14.00	0.430
		yes	4	75.00 ±7.07		
	antidiabetic medication use	no	11	70.91 ±8.61	16.00	1.000
		yes	3	73.33 ±7.64		

Smoking status was unavailable for 3 patients.

Table 3. Correlation between continuous variables and the percentage of carotid artery stenosis (CAS) on computed tomography (CT) angiography

Variable	Patients, *n*	Spearman's rho	*p*-value	Correlation strength	Pearson's *r*	*p*-value
Age	14	–0.1904	0.514	weak negative	–0.3416	0.232
LDL	14	0.4549	0.102	moderate positive	0.4294	0.126
HDL	14	–0.0871	0.767	weak negative	–0.1584	0.589
TAG	14	0.1962	0.501	weak positive	0.2483	0.392
CT angiography vs. Doppler USG	3	0.5000	0.667	moderate positive	0.4339	0.714

Correlation strength refers to Spearman's rho. No correlation reached statistical significance (p < 0.05).
USG – ultrasonography.

stenosis severity (rho = 0.4549, p = 0.102), indicating a moderate positive association, although this did not reach statistical significance. Higher LDL levels were associated with greater percentages of stenosis, which aligns with established pathophysiology of atherosclerosis. Age showed a weak negative correlation (rho = −0.1904, p = 0.514), while HDL cholesterol demonstrated a very weak negative correlation (rho = −0.0871, p = 0.767). Triglyceride levels exhibited a weak positive correlation with the percentage of stenosis (rho = 0.1962, p = 0.501). We also examined the association between CT angiography and ultrasound measurements, finding a moderate positive correlation (rho = 0.5000, p = 0.667) that did not reach statistical significance, likely due to the limited sample size.

None of the examined continuous variables demonstrated statistically significant correlations with the percentage of stenosis. Given the small sample size (n = 14) and lack of statistical significance, these numerical associations should not be interpreted as clinically meaningful trends but rather as preliminary observations requiring validation in adequately powered studies. In summary, the analysis of the CT angiography subset (n = 14) did not identify any statistically significant associations between patient characteristics and the severity of stenosis. The limited sample size precludes definitive conclusions, and all observations from this subset should be considered exploratory and hypothesis-generating only.

Discussion

The carotid arteries deliver oxygen-rich blood to the head, neck and brain, bifurcating into the external and internal carotid arteries typically at the C3–C4 vertebral level. Carotid atherosclerosis accounts for approx. 20% of all ischemic strokes and TIAs. According to most studies, prevalence of CACs in dental images ranges from 2.00% to 31.57%. Thus, early detection of carotid calcifications may help identify previously undiagnosed coronary artery disease and facilitate referral for further evaluation.[19] Atherosclerosis is influenced by various factors, such as diabetes mellitus, obesity, hypertension, smoking, alcohol intake, and chronic renal disorders. Atherosclerosis can lead to strokes when the carotid arteries, which supply blood to the brain, are compromised. It can also cause myocardial infarctions when the coronary arteries, which supply blood to the heart, are affected. These conditions contribute substantially to global mortality.[20]

Sialolithiasis, tonsilloliths and calcification of lymph nodes and blood vessels may manifest in the cervical area. The need to distinguish these calcifications not only from each other but also from different anatomical structures and structures capable of calcification, such as the stylohyoid ligament, triticeous cartilage and thyroid cartilage, makes the diagnosis of atheromas more complex. While the oral surgeon may find it challenging to differentiate atheromatous calcifications on CBCT from other anatomical and pathological structures, the ability to detect carotid atheromas using CBCT presents an opportunity for early treatment, thereby potentially reducing morbidity and mortality.[9] Cone beam computed tomography scans have been increasingly used in recent years for various applications in the dental field. Their value lies in the practitioner's ability to discover clinically significant incidental findings beyond the area of interest for which CBCT was indicated.[14]

The objective of this study was to retrospectively assess the prevalence and severity of CACs identified incidentally on CBCT. A study comparing carotid ultrasonography and CBCT revealed that CBCT may identify and quantify minimal calcification volumes, as little as 1 mm^3, indicating its high sensitivity in selected cases. Nevertheless, CT remains the preferred imaging modality for a more thorough assessment of CACs, especially in regions outside the typical coverage of CBCT.[21] Several imaging modalities have been used to evaluate CACs, including modified posteroanterior radiographs of the neck, where calcifications manifest lateral to the spine, along with CT, which exhibits high sensitivity for identifying intracranial calcifications. Additional techniques include panoramic radiographs, magnetic resonance (MR) angiography, Doppler ultrasonography, and CBCT. In contrast to Doppler ultrasonography and MR angiography, CBCT provides high-resolution 3D imaging of calcifications while potentially reducing costs and radiation exposure compared with conventional CT in selected dental indications.[22]

The present study highlights the critical role of CBCT in the early detection of CACs as incidental findings during routine dental imaging. A total of 890 patients were evaluated, and CACs of mild, moderate or severe grade were identified in 108 patients along the course of the ICA. Among these patients, severe calcifications were detected in 14 individuals, underscoring the potential of CBCT as a valuable diagnostic tool beyond its primary dental applications. Our findings revealed significant associations between severe CACs and established cardiovascular risk factors, including advanced age, elevated LDL levels, increased TAG levels, and hypertension. These results are consistent with existing literature, indicating that dyslipidemia and blood pressure abnormalities significantly contribute to atherosclerotic lesions in the carotid arteries. Moreover, patients with severe CACs underwent further vascular assessment with CT angiography, which allowed for the evaluation of the presence and degree of CAS. However, due to the small sample size and the fact that CT angiography was performed only in patients with severe CACs, the present study cannot establish a direct correlation between the extent of calcification on CBCT and the degree of CAS.

Such findings emphasize the need to refer patients with suspected CACs for further comprehensive medical assessment, as they may be at elevated risk for cerebrovascular events such as stroke. The results of this study are notable

for combining a detailed evaluation of CACs with an assessment of a broad range of associated risk factors. The identification of significant associations between severe calcification and risk factors such as elevated LDL, TAG, hypertension, and advanced age highlights the multifactorial nature of carotid artery disease. By considering these varied parameters together, our study provides broader insight into the possible systemic implications of incidental calcifications identified on CBCT scans.

Our study aligns with previous research showing a clear association between abnormal lipid profiles and CACs. A study by Taengsakul et al. found that high levels of LDL and TAG were closely linked to the development of carotid artery narrowing in patients receiving radiotherapy.[23] Likewise, Smith et al. reported that lipid disorders significantly contributed to plaque buildup and vascular stenosis in this population.[24] These findings reinforce our conclusion that lipid imbalances play an important role in the progression of carotid calcification. Monitoring lipid levels in patients with CBCT-detected calcifications may therefore enable earlier identification of cardiovascular risk and prompt clinical management.[23,24] Brar et al. provided additional evidence supporting the clinical relevance of CACs seen on dental imaging.[6] Their findings demonstrated a strong correlation between calcifications detected on panoramic radiographs and the presence of conditions such as hypertension, hyperlipidemia, diabetes mellitus, stroke, and heart disease.[6]

Cone beam computed tomography provides 3D information, allowing precise localization of calcifications and volumetric assessment. In addition, by applying a structured severity-based classification and correlating selected cases with vascular imaging, this study highlights aspects that have not been systematically addressed in earlier dental imaging research. These features support the novelty of our approach and underline the role of CBCT as a useful adjunct for the incidental detection of potentially significant findings. Damaskos et al. examined 391 CBCT scans and reported both extracranial and intracranial carotid calcifications, showing associations with systemic risk factors.[25] Their findings support the clinical relevance of CBCT in vascular assessment and are in line with the correlations observed in our study.[25]

Similarly, the CBCT-based staging approach for external carotid calcifications proposed by Kadyan et al. illustrates the value of structured classifications.[19] Our work differs by applying a severity-based assessment to internal CACs, with additional correlation with vascular imaging, thereby extending the potential diagnostic contribution of CBCT.[19] Furthermore, our retrospective design is consistent with other CBCT-based studies that have examined anatomical and pathological associations, such as the link between Schneiderian membrane thickness and the severity of periodontitis.[26]

The incidental finding of CACs on CBCT scans provides a distinctive opportunity for the early identification of individuals who may be at increased risk for cardiovascular disease, particularly among asymptomatic patients who might otherwise remain undiagnosed. This highlights a valuable role for dental professionals and radiologists, who should recognize these findings and refer patients for further medical evaluation when necessary. While CBCT is not a substitute for dedicated vascular imaging, its widespread use in dental clinics makes it a practical, non-invasive tool for identifying patients who may benefit from further assessment. As CBCT becomes more common in clinical practice, the implementation of appropriate training and protocols for the recognition of incidental CACs may contribute to earlier diagnosis and the improvement of prevention strategies.

Limitations

This study provides important observations; however, several methodological limitations should be acknowledged. The study is limited by its retrospective design and the relatively small CT angiography subset, which may affect generalizability. However, the use of standardized assessment criteria and a large initial CBCT sample provides meaningful insights. Further prospective studies are needed to confirm these findings.

Conclusions

Cone beam computed tomography has become a valuable tool not only for dental diagnosis but also for the incidental detection of clinically relevant findings such as CACs. This study demonstrates that CACs may be identified incidentally on CBCT examinations and that their presence may warrant further medical evaluation. Given the retrospective design and the limited sample, these findings should be interpreted cautiously and confirmed in larger studies.

Cone beam computed tomography provides 3D visualization, which may facilitate more accurate detection of CACs than conventional dental radiographs. Early recognition of such findings may prompt appropriate medical referral and potentially prevent serious complications.

Ethics approval and consent to participate

The protocol of the study was approved by the Ethics Committee of the University Hospital and the Faculty of Medicine in Pilsen, Charles University (reference No. 93/25).

Data availability

The datasets generated and/or analyzed during the current study are available from the corresponding author on reasonable request.

Consent for publication

Not applicable.

Use of AI and AI-assisted technologies

AI-assisted tool (ChatGPT; OpenAI, San Francisco, USA) was used to refine the language. All scientific content and references were written, reviewed and verified by the authors.

ORCID iDs

Walla Samara https://orcid.org/0009-0001-6556-0872
Omid Moztarzadeh https://orcid.org/0000-0002-4768-2382
Mohammad Najeh Samara https://orcid.org/0009-0004-9890-4936
Lukas Hauer https://orcid.org/0000-0001-6639-2690
Jan Pernicky https://orcid.org/0000-0002-7789-9021

References

1. Möst T, Winter L, Ballheimer YE, et al. Prevalence of carotid artery calcification detected by different dental imaging techniques and their relationship with cardiovascular risk factors, age and gender. *BMC Oral Health*. 2023;23(1):949. doi:10.1186/s12903-023-03564-0
2. Cheng YW, Chen CH, Yeh SJ, et al. Association between modifiable vascular risk factors and rapid progression of postradiation carotid artery stenosis. *J Chin Med Assoc*. 2023;86(7):627–632. doi:10.1097/JCMA.0000000000000936
3. Ahmed M, McPherson R, Abruzzo A, Thomas SE, Gorantla VR. Carotid artery calcification: What we know so far. *Cureus*. 2021;13(10):e18938. doi:10.7759/cureus.18938
4. Mutalik S, Tadinada A. Assessment of relationship between extracranial and intracranial carotid calcifications – a retrospective cone beam computed tomography study. *Dentomaxillofac Radiol*. 2019;48(8):20190013. doi:10.1259/dmfr.20190013
5. Arasu R, Arasu A, Muller J. Carotid artery stenosis: An approach to its diagnosis and management. *Aust J Gen Pract*. 2021;50(11):821–825. doi:10.31128/AJGP-10-20-5664
6. Brar A, DeColibus K, Rasner DS, et al. Carotid artery calcification detected on panoramic radiography is significantly related to cerebrovascular accident, coronary artery disease, and poor oral health: A retrospective cross-sectional study. *Dent J (Basel)*. 2024;12(4):99. doi:10.3390/dj12040099
7. Amitay M, Barnett-Itzhaki Z, Sudri S, et al. Deep convolution neural network for screening carotid calcification in dental panoramic radiographs. *PLOS Digit Health*. 2023;2(4):e0000081. doi:10.1371/journal.pdig.0000081
8. Janiszewska-Olszowska J, Jakubowska A, Gieruszczak E, Jakubowski K, Wawrzyniak P, Grocholewicz K. Carotid artery calcifications on panoramic radiographs. *Int J Environ Res Public Health*. 2022;19(21):14056. doi:10.3390/ijerph192114056
9. Soares ADS, Wanzeler AMV, Renda MDO, Marinho CG, Tuji FM. Cone-beam computed tomography findings in the early diagnosis of calcified atheromas. *J Oral Maxillofac Surg*. 2017;75(1):143–148. doi:10.1016/j.joms.2016.06.179
10. Kadkhodayan S, Almeida FT, Lai H, Pacheco-Pereira C. Uncovering the hidden: A study on incidental findings on CBCT scans leading to external referrals. *Int Dent J*. 2024;74(4):808–815. doi:10.1016/j.identj.2023.11.013
11. Damaskos S, Tsiklakis K, Syriopoulos K, van der Stelt P. Extra- and intracranial arterial calcifications in adults depicted as incidental findings on cone beam CT images. *Acta Odontol Scand*. 2015;73(3):202–209. doi:10.3109/00016357.2014.979867
12. Habib S, Motiwala MA, Khan FR. Does the sagittal root position of maxillary anterior teeth affect the decision making on immediate implants in the anterior maxilla? A CBCT-based study. *Dent Med Probl*. 2024;61(1):65–70. doi:10.17219/dmp/133072
13. Kolcakoglu K, Amuk M, Kizilci E, Sirin Sarıbal G, Askaroglu Ö, Korkut Dİ. Chronological age estimation by measuring pulp chamber volume in teeth with open apices: A CBCT analysis. *Dent Med Probl*. 2025;62(5):889–906. doi:10.17219/dmp/153419
14. Zain-Alabdeen EH, El Khateeb SM. Incidental cone beam computed tomographic findings among Taibah University patients, KSA: A retrospective study. *J Taibah Univ Med Sci*. 2016;12(2):131–138. doi:10.1016/j.jtumed.2016.10.014
15. Arzani S, Soltani P, Karimi A, et al. Detection of carotid artery calcifications using artificial intelligence in dental radiographs: A systematic review and meta-analysis. *BMC Med Imaging*. 2025;25(1):174. doi:10.1186/s12880-025-01719-9
16. Yoo SW, Yang S, Kim JE, et al. CACSNet for automatic robust classification and segmentation of carotid artery calcification on panoramic radiographs using a cascaded deep learning network. *Sci Rep*. 2024;14(1):13894. doi:10.1038/s41598-024-64265-4
17. Newaz ZA, Barghan S, Katkar RA, Bennett JA, Nair MK. Incidental findings of skull-base abnormalities in cone-beam computed tomography scans with consultation by maxillofacial radiologists. *Am J Orthod Dentofacial Orthop*. 2015;147(1):127–131. doi:10.1016/j.ajodo.2014.09.019
18. Fisher CM, Gore I, Okabe N, White PD. Calcification of the carotid siphon. *Circulation*. 1965;32(4):538–548. doi:10.1161/01.cir.32.4.538
19. Kadyan V, Vaddi A, Nagpal A, Molina MR, Lurie AG, Tadinada A. Evaluation of cone-beam computed tomography scans to develop a staging method of external carotid artery calcification. *J Clin Med*. 2024;13(11):3189. doi:10.3390/jcm13113189
20. Samara W, Moztarzadeh O, Pernicky J, et al. Carotid artery stenosis on panoramic radiographs and CT scans in patients with malignancies after radiotherapy. *Anticancer Res*. 2023;43(12):5657–5662. doi:10.21873/anticanres.16770
21. Jashari F, Ibrahimi P, Johansson E, et al. Atherosclerotic calcification detection: A comparative study of carotid ultrasound and cone beam CT. *Int J Mol Sci*. 2015;16(8):19978–19988. doi:10.3390/ijms160819978
22. Paknahad M, Shahidi S, Abbasi R, Paknahad M. Evaluation of the prevalence of atherosclerosis within the course of internal carotid artery in cone beam computed tomography images. *Indian J Otolaryngol Head Neck Surg*. 2022;74(Suppl 3):5242–5251. doi:10.1007/s12070-020-01958-y
23. Taengsakul N, Nivatpumin P, Chotchutipan T, Tungfung S. Carotid artery stenosis and ischemic cerebrovascular events after radiotherapy in patients with head and neck cancer. *PLOS One*. 2025;20(1):e0314861. doi:10.1371/journal.pone.0314861
24. Smith J, Margalit D, Golledge J, Nastasi D, Nohria A, McDowell L. Carotid artery stenosis and ischemic stroke in patients with head and neck cancer treated with radiation therapy: A critical review. *Int J Radiat Oncol Biol Phys*. 2024;119(6):1437–1454. doi:10.1016/j.ijrobp.2024.03.044
25. Damaskos S, Zoukos A, Vlachopoulos C, Angelopoulos C. Vascular-related cone-beam computed tomographic findings in healthy and medically compromised patients: A study based on self-reported medical history data. *Imaging Sci Dent*. 2025;55(2):197–205. doi:10.5624/isd.20250029
26. Veluri S, Gottumukkala SNVS, Penmetsa G, et al. Retrospective analysis of the relationship between Schneiderian membrane thickness and periodontitis severity using cone beam computed tomography (CBCT). *Dent Med Probl*. 2025;62(1):65–72. doi:10.17219/dmp/147105